

## Chapter 78

# Neck Dissection

David E. Eibling

---

Management of the neck remains the keystone of management of cancer of the head and neck. The cervical lymphatics play an active role in the biologic behavior of cancers of the head and neck. Cells from the primary cancer find their way into the multilevel, anastomosing network of lymphatics that drain through a series of lymph nodes. Cancer cells found in the lymphatic fluid are trapped by the nodes, where they often evade host immune defenses and proliferate. Distant metastatic disease often occurs quite late in patients with squamous cell carcinoma of the head and neck, despite the presence of involved cervical neck nodes, suggesting that the filtration function of the cervical lymphatics is effective. Unfortunately, the proliferation of cancer within the nodes often leads to uncontrolled regional disease and the eventual demise of the patient. The finding of cancer within the cervical lymph nodes downgrades the patient's curability by 50% and is responsible for 50% to 95% of recurrent disease. Depending on primary site and treatment, treatment plans must consider management of cervical metastatic disease. Leaving cancer in the cervical nodes, whether or not clinically apparent, inevitably results in unacceptable morbidity and mortality for the patient.

The staging system for cancer of the head and neck (with the exception of thyroid cancer) emphasizes the status of the cervical lymphatics. Patient outcomes strongly correlate with the presence and extent of metastatic disease in the regional nodes.<sup>1,2</sup> The critical differentiation for staging is the presence, number, and size of involved cervical nodes. A single, small node (N1) converts any early primary cancer (T1-2) to stage 3, and more than one lymph node or a lymph node greater than 3 cm (N2 or 3) to stage 4, reflecting the grim prognostic implications of palpable neck disease (Fig. 78-1). Metastatic deposits that are present, but not clinically evident, convey the same dismal implications for the patient because they will enlarge to become palpable at a later date. Cancer that has spread through

the capsule into the surrounding fat (extracapsular spread, or ECS) is even worse, probably reflecting tumor biologic behavior rather than a geographic location (Fig. 78-2).<sup>3</sup>

Clinical staging includes information derived from imaging, which is considered to be complementary to physical examination. A definitive pathologic diagnosis is derived from fine-needle aspiration biopsy or examination of excised lymph nodes.<sup>4</sup>

Non-squamous cell carcinomas of the head and neck include malignant melanoma, cancers of salivary gland origin, and cancer of the thyroid. In contrast to other histologic variants, differentiated cancer of the thyroid metastatic to the cervical lymph nodes does not convey as grave a prognosis. Hence the staging system for thyroid cancer is weighted toward the primary cancer, with nodal disease being indicated only as present or absent, regardless of the size of the lymph nodes.

The staging system is inadequate to predict tumor behavior due to the heterogeneous nature of squamous cell carcinoma of the head and neck. Although additional markers are used routinely in cancers of other sites, as of this writing similar biologic indicators, such as the presence of ECS, have not been incorporated into the standard staging system for cancer of the head and neck.

### OCCULT METASTASIS TO THE CERVICAL LYMPH NODES

More than 50% of patients with identified primary cancers of the head and neck present with obvious metastasis to cervical lymph nodes. Unfortunately, pathologic evidence of cancer deposits is found in 20% to 30% of patients without clinical or radiologic evidence of nodal involvement. Pathologic evidence of metastasis may be identified in lymph nodes that have been surgically removed, or evidenced by delayed tumor

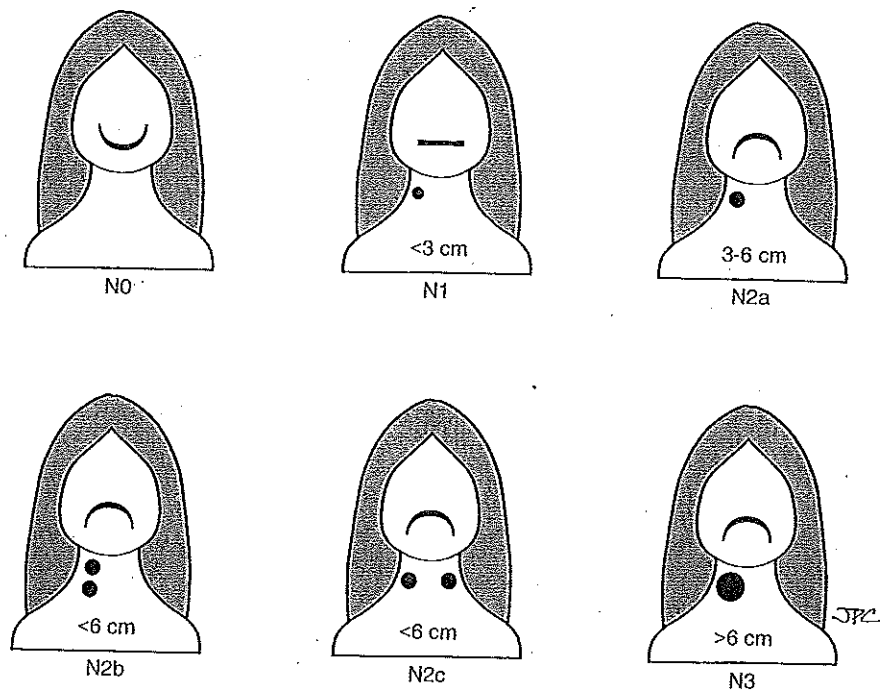


Figure 78-1. Staging system for head and neck cancer.

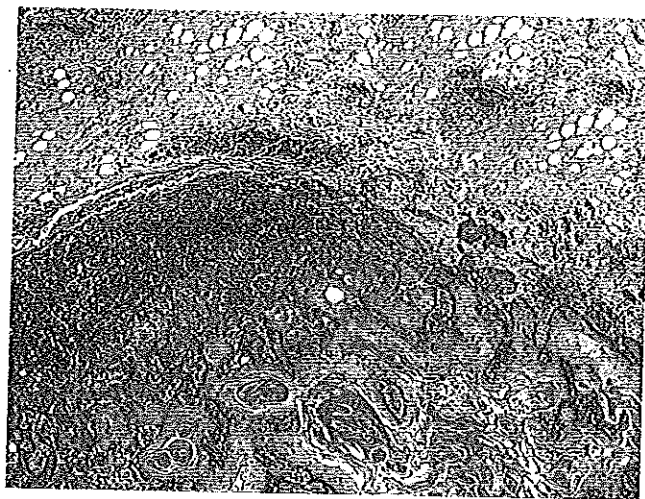


Figure 78-2. Extracapsular spread in the carotid lymph node invading the surrounding soft tissue.

presentation in the neck despite the absence of recurrence of the primary cancer. The site and stage of the primary cancer predict the position and frequency of these "occult" metastases, and histologic diagnosis is dependent on specific sampling techniques. Successful therapy must consider treatment of nonpalpable nodes that may contain microscopic metastasis as well as clinically involved positive nodes. Decisions are dependent on probabilistic information and the willingness of the patient and surgeon to accept the risk of untreated occult disease.

Lymph node removal by neck dissection is performed for therapeutic removal of palpable enlarged

lymph nodes, lymph nodes deemed enlarged through imaging modalities, or apparent normal lymph nodes considered to be at risk for metastatic spread. Removal of potentially involved but nonpalpable lymph nodes is beneficial not only for therapeutic purposes, but also as an effective means of determining pathologic stage and the need for further adjuvant therapy. The choice of treatment of the neck depends on the site and stage of the primary cancer, the probability of occult metastases, the treatment modality selected for the primary cancer, and the desires of the patient.

## RADICAL NECK DISSECTION

The "classic" radical neck dissection effectively removes all of the lymph nodes present in the neck and their interconnecting lymphatics. In his classic article in 1906, Crile<sup>5</sup> for the first time described systematically the procedure that remained the standard form of neck dissection for more than 70 years. The radical neck dissection removes not only nodes and lymphatics with surrounding fat, but also the sternocleidomastoid muscle (SCM), submandibular gland, tail of the parotid gland, internal and external jugular veins, cervical sensory nerves, and the spinal accessory nerve, whether these structures are involved or not. These structures are removed to conform to the Halstedian concept of en bloc resection. Most of the morbidity of the procedure is thereby related to the removal of these additional structures, particularly the 11th cranial nerve, sternocleidomastoid muscle, and internal jugular vein (IJV), rather than the removal of the nodes per se. The radical neck dissection was the most commonly used form of neck dissection in the United States until the

1970s.<sup>6</sup> It has, however, largely been replaced by modifications of the procedure that preserve nonlymphatic structures such as muscles, nerves, and vessels.

## FUNCTIONAL NECK DISSECTION

Cervical lymphatics are contained within fascial “envelopes,” consisting of the fascia covering the submandibular glands, carotid sheath, SCM, and deep cervical muscles and nerves. Suarez is generally credited as being the first to incorporate this anatomic fact into a modification of the classic neck dissection, removing only the lymph nodes. Ferlito and colleagues<sup>7</sup> and Bocca and Pignataro<sup>8</sup> coined the term “functional neck dissection” and described the technique in the English-speaking literature in 1967. Today we term procedures that remove all the lymphatics but preserve non-lymphatic-containing structures “modified neck dissection.”<sup>9</sup>

Cervical lymph nodes are divided into groups that roughly correspond to describe “levels” or zones that are the basis of various forms of neck dissection that remove only nodes at risk. Although these levels (and groups) are not discretely separated by anatomic structures, they nevertheless define a convenient classification system (Fig. 78-3).

## ANATOMIC STRUCTURES

A basic review of the anatomy of the neck is beneficial in understanding the surgical approaches to the neck, particularly the various forms of neck dissection. The

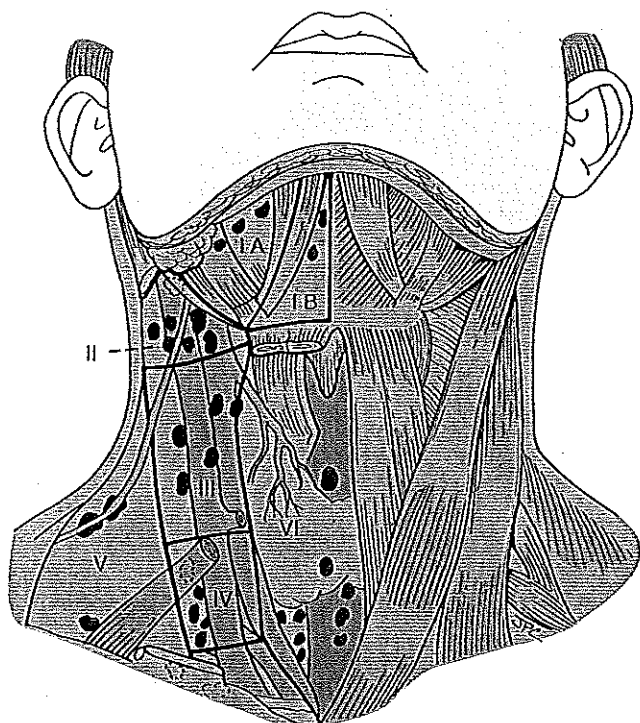
major muscles, nerves, and vessels are discussed in the following paragraphs.

## Platysma Muscle

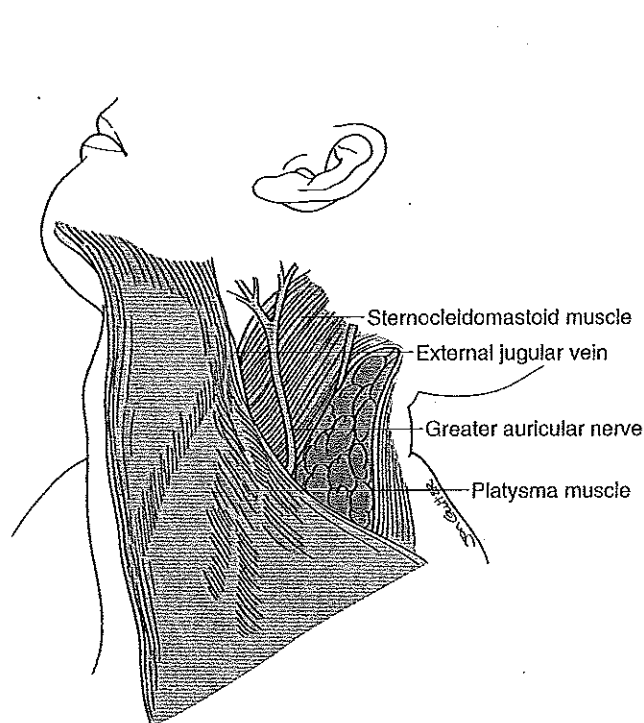
The platysma muscle lies just deep to the subcutaneous fascia and fat and extends from just over the mandible down to the upper chest. It runs obliquely from postero-inferior to anterosuperior, inserting into the superficial muscular aponeurotic system. It is deficient in the lower anterior midline in the neck and does not extend appreciably posterior to the exterior jugular vein and greater auricular (GA) nerve (Fig. 78-4). Its undersurface provides a convenient plane in which to elevate skin flaps, and it may also be used alone or with overlying skin as a flap in an intraoral closure technique.

## Sternocleidomastoid Muscle

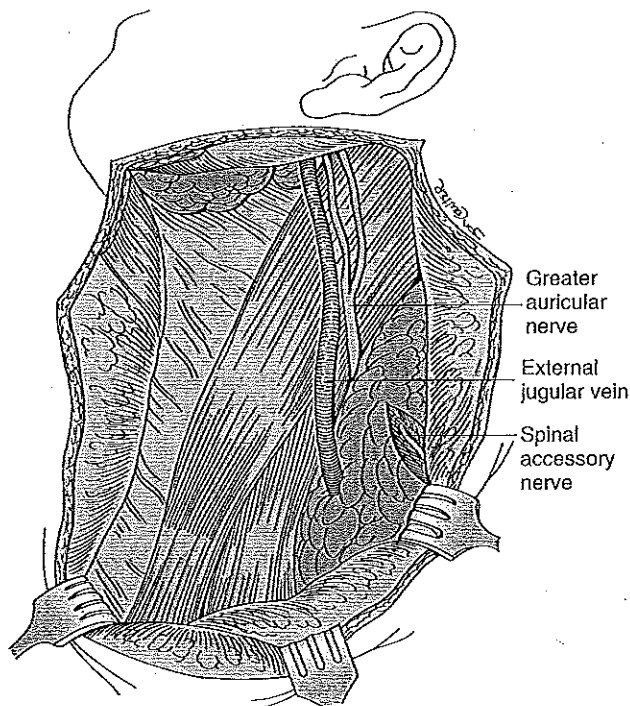
The SCM runs obliquely from antero-inferior to postero-superior, inserting on the mastoid tip. It can be readily differentiated from the platysma muscle by the direction of its fibers. It is crossed in an inferior-to-posterior direction by the GA nerve and the external jugular vein, which lie immediately deep to the platysma. If these structures are left on the surface of the SCM during flap elevation, the SCM assists in developing the fascial envelope in modified and selective neck dissections (Fig. 78-5). The posterior border of the SCM represents the posterior border of nodal levels II through IV and the anterior border of level V (Fig. 78-6). As the cervical contributions to the GA nerve leave the cervical plexus and sweep around the posterior border of the SCM, they artificially separate levels IV and V, identifying the posterior limit of the selective neck dissection.



**Figure 78-3.** Levels of neck nodes. Selective neck dissections are labeled according to the levels of nodes removed.



**Figure 78-4.** Detail of the platysma muscle, the external jugular vein, and the greater auricular nerve.



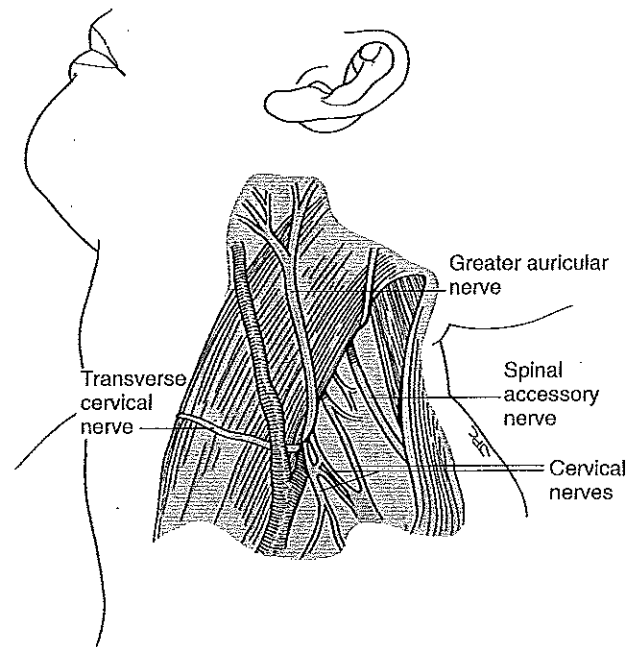
**Figure 78-5.** The 11th nerve is best identified posteriorly in the posterior triangle where it lies more superficially.

### Greater Auricular Nerve

The GA nerve extends vertically from the posterior edge of the SCM obliquely over the SCM, roughly parallel and slightly posterior to the external jugular vein (see Fig. 78-4). It divides into two branches, the anterior of which enters the substance of the parotid gland. The GA nerve provides sensation to the auricle and dividing or injuring it results in hypesthesia, which can be quite problematic for some patients. We attempt to preserve the GA nerve during selective neck dissection, although it is impossible in the radical neck dissection or modified radical neck dissection. In the illustrations in this text, the nerve is illustrated as having been divided, but this is not always necessary.

### Spinal Accessory Nerve

The spinal accessory nerve (the 11th cranial nerve) passes over the jugular vein in most instances at the level of the posterior belly of the digastric muscle. It then passes through the lymphoid tissue of level IIB (level II posterior to the jugular vein) and then in most cases pierces the SCM after giving off a branch that innervates the muscle. It occasionally passes *under* the IJV and rarely the vein will be found to split around the nerve. Although classic anatomic diagrams suggest that the nerve passes under the vein in 30% of the cases, the clinical experience of surgeons suggests that this figure is much less. Nevertheless, blindly cutting all tissue lateral to the nerve at the level of a digastric muscle may interrupt the IJV in some cases. These anatomic details are important to recall in vein-sparing procedures.



**Figure 78-6.** Detail of the cervical nerves and the greater auricular nerve at the posterior border of the sternocleidomastoid muscle. Note the 11th nerve as well as the anterior border of the trapezius muscle.

At the point where the accessory nerve enters the SCM, there is a vascular pedicle that may provide troublesome bleeding during dissection. These vessels are best ligated after identification in the performance of a selective or modified neck dissection. The 11th nerve exits the muscle deep to Erb's point (at which the GA nerve sweeps around from the posteroinferior aspect of the SCM) and then traverses level V in a fairly superficial plane to reach the anterior border of the trapezius muscle (see Fig. 78-6). It is the loss of trapezius muscle function that is responsible for much of the morbidity of the procedure. The fascial envelope of level V must be incised to free the nerve during a modified neck dissection if spinal accessory nerve preservation is to be accomplished. Even if the nerve is preserved, some deficit can be demonstrated in patients in whom it is dissected.<sup>10</sup> On reaching the anterior border of the trapezius muscle, the nerve does not directly pierce it, but rather extends inferiorly just anterior to the anterior border, from which ramifications enter the muscle. Dissecting "hard on" the muscle in its most lateral extent can result in inadvertent denervation in planned nerve-sparing procedures. The 11th nerve lies more superficial at its more posterior-inferior extent and can be injured during flap elevation. It frequently travels directly superficial to enlarged posterior cervical nodes and can be inadvertently divided when these nodes are removed for biopsy purposes. Particular care must be taken when a mass in the posterior triangle of the neck is biopsied under local anesthesia. The local anesthesia may result in loss of motor nerve function so that the characteristic motion of the trapezius on touching the nerve is eliminated. The nerve can thereby be inadver-

tently divided and the injury remains unrecognized until the local anesthetic dissipates. If resection is required, nerve repair has been demonstrated to be beneficial.<sup>11</sup>

### Trapezius Muscle

The trapezius muscle extends from the posterior occiput and nuchal line along the posterior margin of the neck dissection and extends to the lateral third of the clavicle. Identification of this muscle may be difficult during flap elevation because of its superficial position and significant posterior positioning superiorly in the neck. Early identification of the 11th nerve and dissecting along its course to the trapezius are useful. In identifying the muscles, it is not uncommon to mistake the levator scapulae for the trapezius during flap elevation. Such a mistake might lead to inadvertent transection of not only the 11th nerve but also the nerves to the levator scapulae, resulting in shoulder disability. The trapezius muscle assists in stabilization of the shoulder girdle during arm abduction. The arm frequently cannot be elevated beyond horizontal after nerve injury. Functional disability arises such that there is shoulder drop and "winging" of the scapula (Fig. 78-7). The greatest morbidity, however, is not the decreased range of motion but rather severe shoulder discomfort due to the loss of function and torque on the acromioclavicular joint. The combination of loss of trapezius function and shoulder pain is referred to as "the shoulder syn-

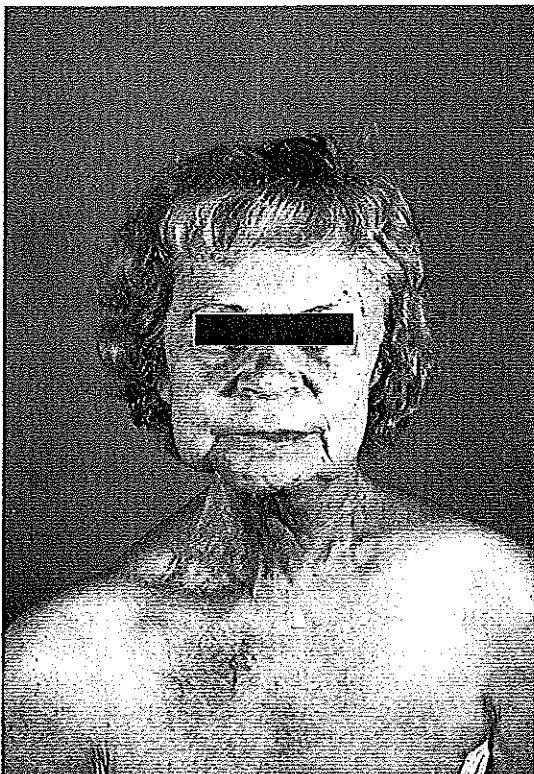

Figure 78-7. A patient with paralysis of the left trapezius and a dropped shoulder, resulting from 11th nerve sacrifice.

drome" and can be detected in a high percentage of patients who have undergone neck dissection. Preservation of the 11th nerve reduces, but does not totally eliminate, this effect of nerve injury.

### Omohyoid Muscle

The omohyoid muscle consists of two bellies, the posterior of which lies superficial to the brachial plexus, phrenic nerve, and transverse cervical artery and vein (Fig. 78-8). Its anterior belly lies immediately superficial to the jugular vein at the division point between nodal levels III and IV before turning superiorly to attach to the hyoid bone. Early identification of this muscle assists in the identification and preservation of the brachial plexus and phrenic nerve. It is often entitled the "resident's friend," similar to the description of the digastric muscle (discussed next).

### Digastric Muscle

The posterior belly of the digastric muscle extends from the greater corner of the hyoid bone to the deep under-surface of the mastoid tip. It inserts into a groove in the mastoid process of the temporal bone recognized from the mastoid side as the *digastric ridge*. The only critical anatomic structure superficial to the posterior belly of the digastric muscle is the marginal mandibular branch of the facial nerve (see later discussion). This muscle, often entitled the "resident's friend," lies directly superficial to the branches of the external carotid artery, the hypoglossal nerve, the internal carotid artery, and the jugular vein (Fig. 78-9). The 11th nerve passes over the jugular vein and immediately deep to the posterior belly of the digastric muscle in the majority of patients. During selective neck dissection, definition of the angle

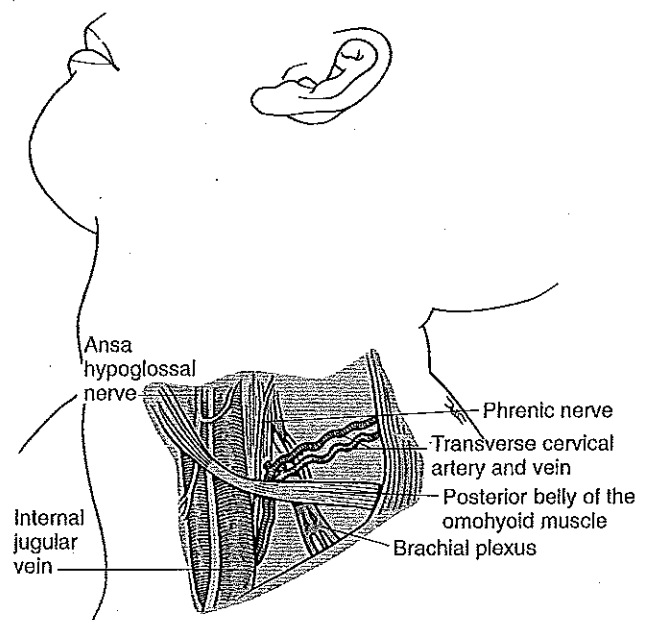
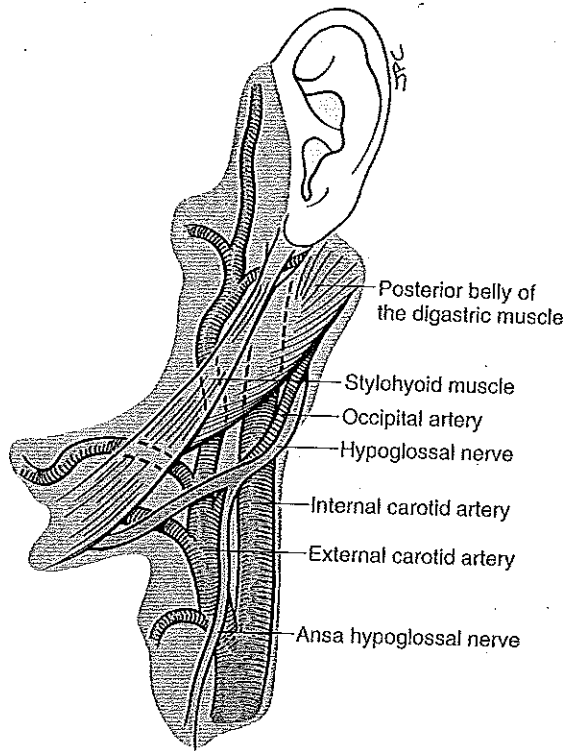


Figure 78-8. Detail of the inferior neck: omohyoid muscle, transverse cervical artery, brachial plexus, and jugular vein.



**Figure 78-9.** Detail of the superior neck, including the digastric muscle, the internal and external carotid arteries, and the hypoglossal nerve.

created by the deep anterosuperior aspect of the SCM and the posterior belly of the digastric muscle helps free nodes located high and posteriorly in level II (2B) (see Fig. 78-9).

The anterior belly of the digastric muscle separates the submandibular triangle level IB from the submental triangle level IA. In patients with lesions of the anterior floor of the mouth, lip, or facial skin, it is important to remove the submental nodes anterior to the anterior belly of the digastric muscle. Removal of the muscle, fascia, and nodes immediately posterior to the anterior belly of the digastric muscle assists in identification of the mylohyoid muscle, a key step in safe dissection of the submandibular triangle. Exposure of the anterior belly of the digastric muscle can assist in defining the posterior belly as well, a time-saving step in cases in which a complete dissection of level I is not performed.

### Facial Nerve

The facial nerve exits the stylomastoid foramen immediately anterior and superior to the digastric muscle and extends laterally and anteriorly within the substance of the parotid gland. The inferior division passes lateral to the posterior facial vein before bifurcating. The marginal mandibular nerve extends anteriorly and immediately deep to the fascia covering the submandibular gland before extending superiorly into the platysma muscle. Usually more than one branch is present,

the most inferior of which may loop inferior to the submandibular gland. A sensory branch of the transverse cervical nerve may accompany this nerve, making identification difficult. The cervical branch, which must be sacrificed in neck dissection, extends inferiorly to innervate the platysma. Preservation of the marginal branches of the facial nerve is an important component of neck dissection. Unnecessary trauma to this nerve is to be avoided because it results in obvious lower lip and commissure deformity. However, removal of the nodal groups in level I requires that this nerve be dissected free from the prevascular and postvascular node region at the crossing of the facial artery and vein over the mandible at the mandibular notch. Although dividing the vein and artery low and sweeping the tissue superiorly will protect the nerve in this location, it is not adequate protection for the nerve posterior to the vein and leaves the lateral level I nodes undissected. These may be involved with tumor in the floor of the mouth and lateral oral cavity lesions such as those of the buccal mucosa and mandibular alveolus. Once the nerve is identified, it can be traced posteriorly to where it turns superiorly into the parotid gland. Tissue lateral and inferior to this point can be safely divided to expose the posterior belly of the digastric muscle. This is helpful early in the performance of a selective neck dissection.

### Hypoglossal Nerve

The hypoglossal nerve exits near the jugular foramen, passes under the IJV and over the internal and external carotid arteries, giving off the ansa hypoglossal branch. It then loops inferior and passes under the posterior belly of the digastric muscle, passing across the floor of the submandibular triangle. At the point where it passes under the digastric muscle, it is surrounded by numerous veins forming a venous sheath called the *Ranine veins*. It enters the submandibular triangle under the fascia of the floor of the triangle roughly parallel to the direction of the submandibular duct, crossing the submandibular triangle before entering the tongue musculature. Inadvertent clamping while controlling venous bleeding in the plexus posterior and inferior to the posterior belly of the digastric muscle can result in inadvertent injury to the hypoglossal nerve. Injury can also occur through inappropriate dissection through the fascia of the floor of the submandibular triangle, particularly when the nerve is adherent to the submandibular duct due to fibrosis.

### Brachial Plexus and Phrenic Nerve

Injuries to key peripheral nerves during the performance of neck dissection can result in serious complications, typically with lifelong sequelae. Injuries to the brachial plexus or phrenic nerve are among the most devastating of these inadvertent injuries. Careful anatomic dissection is required and, if there are any questions as to location, the patient should not be paralyzed so that inadvertent (or intentional) stimulation of the nerve can be identified. Injuries to the brachial plexus

and phrenic nerve are to be avoided. The brachial plexus exits between the anterior and middle scalene muscles and extends inferiorly deep to the clavicle and under the posterior belly of the omohyoid muscle. The transverse cervical artery and vein usually lie immediately superficial to the plexus and often can be preserved by careful dissection and division of the ascending branches in order to permit inferior displacement (see Fig. 78-8).

The phrenic nerve is formed by contributions from the cervical plexus ("three, four, and five keep the diaphragm alive") and must be preserved to avoid postoperative pulmonary compromise. The nerve should be identified early in the dissection of levels IV and V as it crosses the anterior scalene muscle immediately anterior to the brachial plexus and in proximity to the transverse cervical artery and vein. The nerve lies immediately under the enveloping fascia of the anterior scalene muscles, hence elevation of the fascia from the muscle can lead to inadvertent elevation of the nerve into the surgical specimen and inadvertent injury. A more common cause of injury to the phrenic nerve is through removal of the cervical plexus by inadvertently dividing the spinal contributions to the cervical plexus as they extend between the middle and anterior scalene muscles. This occurs when the surgeon dissects in too deep a plane across the scalene muscles, inadvertently elevating and removing the cervical plexus. This injury can be avoided by keeping the plane of dissection above the fascia and dividing the cervical nerves only after they exit the plexus and extend into the specimen. This technique avoids the inadvertent elevation of the plexus and its contribution to the phrenic nerve. Early identification of the phrenic nerve to keep it visualized throughout the procedure also assists in protecting the integrity of the nerve.

The cutaneous branches of the cervical plexus identify the posterior limit of dissection of levels II to IV. These nerves exiting the plexus should be identified and maintained intact. This technique assures that the cervical plexus and its contributions, particularly the phrenic nerve, remain undissected. Although these are routinely divided in the performance of a classic radical neck dissection, they are also divided again as they exit the cervical plexus. If during the performance of a selective neck dissection the cervical nerves are inadvertently divided, then they must be identified and followed to the cervical plexus and left in situ to avoid inadvertent dissection of the cervical plexus.

### Internal Jugular Vein

The venous anatomy of the neck varies considerably in terms of both the relative size and the anatomy of the IJV and its tributaries. The disparity in size between right and left internal jugular veins can be marked in some cases. Typically, there are multiple small tributaries and several large branches; of particular importance is the common facial vein, located approximately two thirds of the way from the clavicle to the digastric muscle, which enters along with the superior thyroid

vein in a trifurcation. Care must be taken when dissecting the fascia from the vein in the performance of a vein-sparing procedure to avoid tearing the smaller tributaries. Tearing these smaller tributaries can result in excessive blood loss and significant wasted time in an attempt to preserve the vein. Although the retromandibular vein can occasionally be preserved, the multiple tributaries in this region, the frequent occurrence of positive nodes at the trifurcation, and the risk of inadvertent injury to the hypoglossal nerve mitigate against the routine preservation of the retromandibular vein. When ligating the common facial vein, it is wise to leave a generous stump to avoid artificially constricting the IJV by ligature.

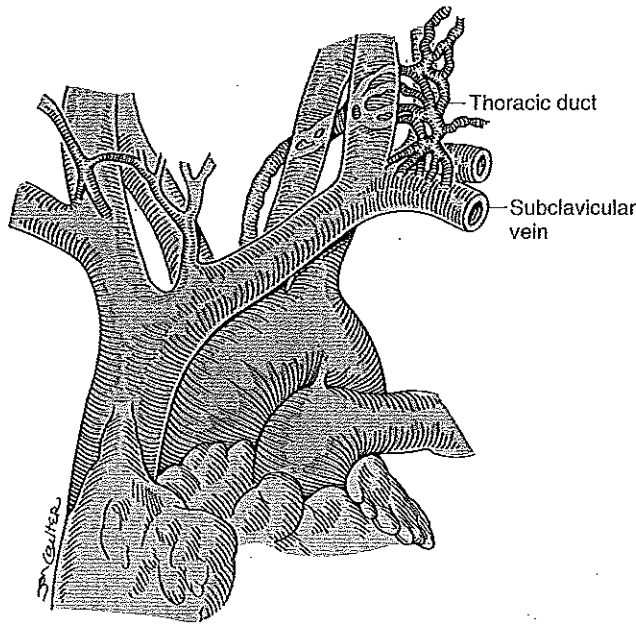
### Carotid Artery

The carotid artery and vagus nerve travel within the carotid sheath immediately deep to the jugular vein. The vagus nerve can be dissected free from the carotid artery; care must be taken when dividing the IJV in the inferior portion of the neck to avoid elevating the vagus nerve with the vein before ligation and division. Here again identification is the best protection. The cervical sympathetic chain lies posterior and deep to the carotid sheath as the neck is dissected from posterior to anterior. Care must be taken not to dissect deep to the carotid artery or the cervical sympathetic chain will be elevated, resulting in Horner's syndrome.

Bradycardia or hypotension may occur during dissection in the region of the carotid bulb due to stimulation of the pressure receptors in this area. If this occurs, dissection around the artery should cease, and injection of 1% lidocaine (Xylocaine) without epinephrine into the adventitial tissue of the carotid artery can abort or prevent the problem. Patients with head and neck cancer frequently have concomitant vascular disease, so that excessive manipulation of the carotid artery should be avoided because this can precipitate embolic phenomena, including stroke. Gentle handling and minimal manipulation of the artery are necessary to avoid these difficulties. Dissection of adherent tumor from the carotid artery can be performed in the subadventitial plane. Dissection is tedious and high levels of both technical skills and surgical judgment are required to assure optimal outcome.

The superior thyroid artery, the first branch of the external carotid system, loops slightly superiorly before beginning its inferior transit toward the superior pole of the thyroid gland. At this point it is close to the superior laryngeal nerve, and preservation of the artery can assist not only in identification of the superior pole of the thyroid, but also in preservation of the superior laryngeal nerve.

Branches of the external carotid artery lay immediately deep to the hypoglossal nerve and in close proximity to the ranine veins. During dissection of the hypoglossal nerve and division of the ranine veins, care must be taken to avoid injury to these vessels, particularly sidewall types of injuries that can result in later postoperative bleeding.



**Figure 78-10.** Detail of the thoracic duct and vascular structures in the inferior neck.

### Thoracic Duct

The thoracic duct ascends into the lower left neck immediately posterior to the jugular vein. The duct may extend several centimeters above the clavicle before turning anterior and lateral to empty into the jugular vein (Fig. 78-10). The anatomy of this thin-walled network of ducts varies considerably and it is usually impossible to individually identify and ligate the tributaries. It is important to recall that chyle is not milky in fasting patients who have received nothing by mouth for at least 8 to 12 hours; therefore identification of a leaking duct may be particularly difficult in elective procedures. The duct lies anterior to the phrenic nerve and the transverse cervical artery and vein. The preferred method to avoid a chyle leak is by en bloc ligation of the lymphatic pedicle in which the lymphatic duct(s) lie. This can be safe to perform only after the carotid artery, vagus nerve, IJV, and phrenic nerve are identified. Suture ligation of the pedicle is often warranted to prevent the tie from slipping loose and resulting in a leak. If a leak does occur, microscopic examination of the surgical field may be required to identify and repair the site of the leak. Fibrin glue has been reported to be useful in these situations.<sup>12</sup>

### NODAL LEVELS

The anatomy of the neck is easier to comprehend when divided into triangles: submental, submandibular, anterior, and posterior cervical triangles. The predominant nodal groups are located in the anterior triangle, adjacent to the carotid sheath, extending from just inferior to the posterior belly of the digastric muscle to the thoracic inlet. Additional nodes are located in each of

the other cervical triangles. Nodal groups are divided into regions or levels (see Fig. 78-3). Level I includes both the submental and submandibular regions, often-times referred to as levels IA and IB. Although similar, surgical and radiographic definitions of the divisions between the levels are not identical. For example, the radiographic division between levels III and IV is the inferior margin of the cricoid cartilage. However, chest wall configuration and neck positioning can result in variation of this position in relationship to the actual nodal groups. Level II includes the jugular digastric region from the level of the posterior belly to the digastric muscle down to the level of the hyoid bone. Level III extends from the hyoid bone to the level of the cricoid. Level IV nodes are those inferior to the level of the cricoid cartilage and extend down to the level of the clavicle where it is contiguous with the mediastinal nodes. Level V includes the posterior triangle nodes, which lie posterior to the SCM and envelop the path of the spinal accessory nerve, as well as the supraclavicular nodes. Level VI is the central anterior neck compartment and consists of the pretracheal (Delphian) and paratracheal nodes inferior to the thyroid gland and adjacent to the thymus.

### Predictability of Nodal Drainage

Clinical experience suggests that the pattern of initial tumor spread from various primary sites to specific nodal groups is predictable. These patterns have been illustrated in a large clinicopathologic series of neck dissections performed on patients with clinically disease-free necks.<sup>13</sup> Anterior oral cavity malignancies tend to drain first to nodes in levels I, II, and III before involving nodes in levels IV and V. Although uncommon, inferior level III nodes under the omohyoid muscle can be the only nodes involved with anterior oral tongue lesions. Cancers arising in the oropharynx, hypopharynx, and supraglottic larynx initially metastasize to levels II, III, and IV. Level I nodes are infrequently involved in primary cancer of the hypopharynx or supraglottic larynx without clinical evidence of neck disease. Tumors of the thyroid gland may metastasize to levels II to IV, including the paratracheal lymph nodes, and to level V. A palpable level V node may be the only clinical evidence of a thyroid malignancy. This predictability facilitates the selection of specific modifications of neck dissection for specific patients.

### Sentinel Node Biopsy

Evidence exists to suggest that the lymphatic drainage of various sites of the head and neck spread in a predictable manner to specific nodes. These nodes, termed *sentinel nodes*, are the first echelon in the drainage pattern and the presence or absence of tumor in these sentinel nodes can predict whether or not other nodes in the neck may be involved. Although standard therapy for melanoma<sup>14</sup> and breast cancer, sentinel node biopsy remains investigational in the management of squamous cell carcinoma of the head and neck.<sup>15</sup> Identification and careful examination of sentinel nodes has a



high reliability in predicting the presence of tumor spread beyond the primary site, but reliability of the sampling is not infallible.<sup>16</sup> There are several technical challenges inherent with its usage. The first of these is the requirement that appropriate imaging material be injected into the area around the primary site at the correct timing to permit visualization. Intraoperative identification of the node can be assisted by an interoperative detector. Many surgeons use isosulfan blue injected along with the sulfur colloid to permit visual staining of the sentinel node.<sup>15</sup>

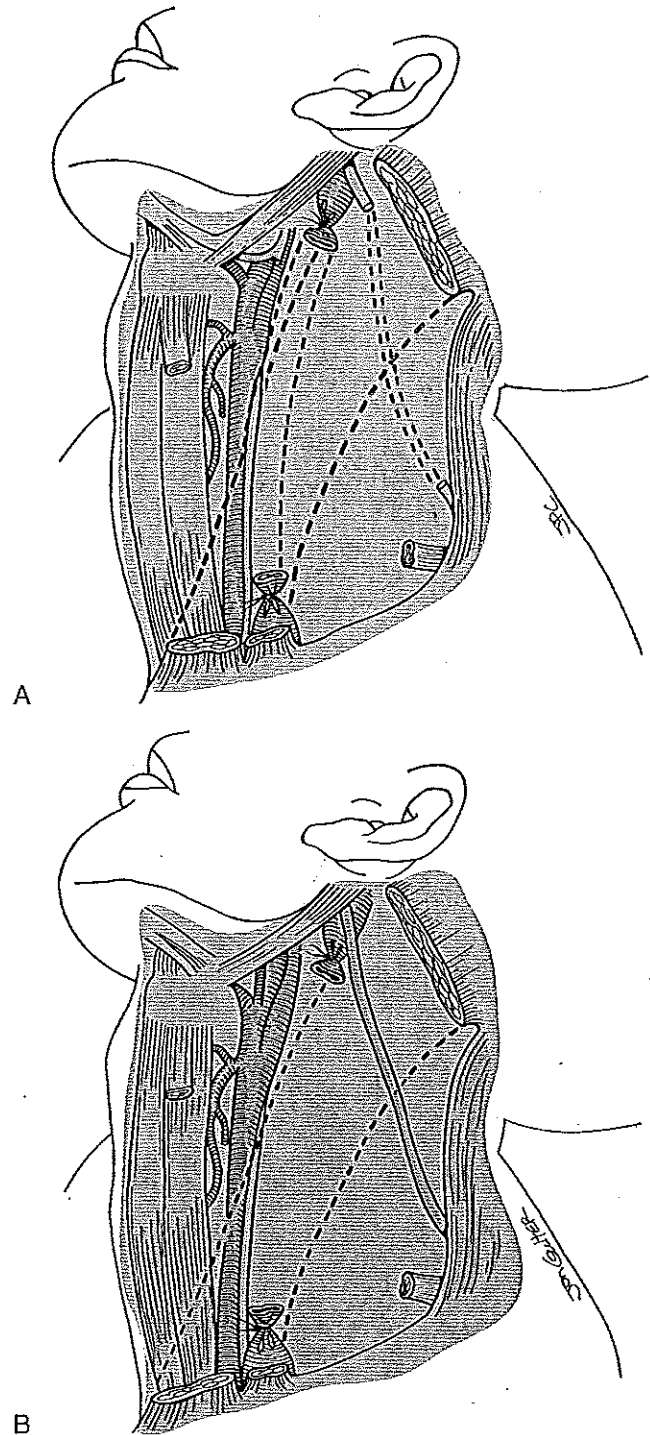
Once the lymph node has been removed, a careful histologic examination must be performed to identify microscopic evidence of tumor involvement. Time-consuming serial sectioning of sampled nodes is required, hence sentinel node biopsy is not an interoperative tool as of this time. It is possible that in the future polymerase chain reaction or assisted sentinel node sampling may facilitate interoperative assessment of the positivity of sentinel nodes.

One of the more problematic features of head and neck cancer is the presence of more than one sentinel node in a significant percentage of patients. This requires the identification and dissection of several nodes, often through separate incisions at separate sites, leading to fairly extensive dissection and longer surgical procedures. As a result of this and the aforementioned issues, sentinel node biopsies for squamous cell cancer of the head and neck is currently performed in only a few centers in an investigational manner.

### CLASSIFICATION OF NECK DISSECTION

Neck dissections can be classified into one of three basic types: comprehensive, selective, and extended. Comprehensive neck dissections remove all of the nodes removed by the classic radical neck dissection and may preserve several or all of the nonnodal structures typically resected in radical neck dissection. In the past, modified neck dissection was identified by number. The current classification system notes the levels removed and the structures preserved (Fig. 78-11).

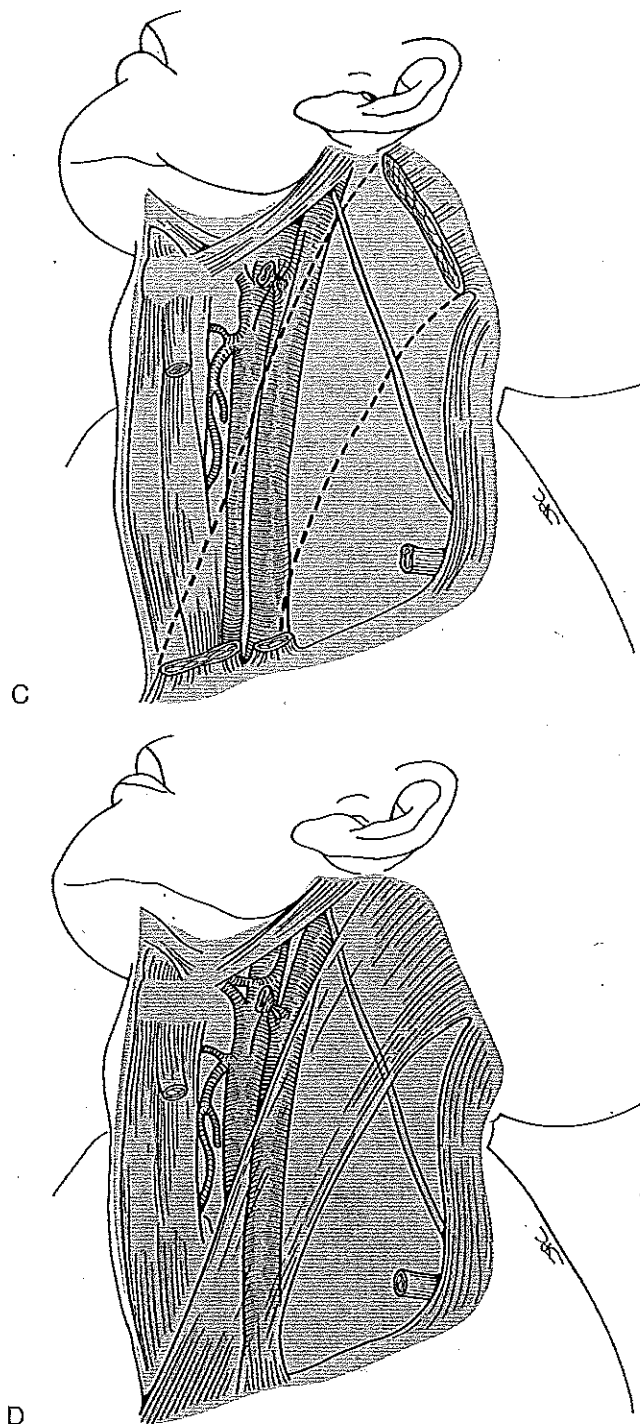
Selective neck dissections are designed to remove specific nodal groups. Which nodal groups are removed is dependent on the site and stage of the primary cancer. Although these procedures were initially used only for the elective management of the clinically negative neck, they are now used for removal of clinically involved nodes in selected cases. Clinical pathologic studies performed by Byers and colleagues 25 years ago provide the basis for the selection of specific nodal groups at highest risk for occult metastatic disease.<sup>13</sup> The anterior (or supraomohyoid) neck dissection was designed to remove nodes in levels I to III and is characteristically used when cancer originates in the oral cavity. Levels II through IV are removed for primary cancer originating in the supraglottic larynx and hypopharynx. Levels II through V are removed in cases of cancer of the posterior scalp along with the suboccipital nodes under the trapezius muscle posterior to level V. As such, this "posterior lateral neck dissection" is a form of extended



**Figure 78-11** A, Radical neck dissection (RND)—the sternocleidomastoid muscle (SCM), the internal jugular vein (IJV), and the 11th nerve are all resected with the specimen. B-D, Three types of modified neck dissections, preserving one or more structures. B, Preserving the 11th nerve.

neck dissection even though nodes in level I are not resected.

Extended neck dissections such as paratracheal dissections may be performed for lesions likely to involve the nodes in level VI, primarily cancer involving the subglottic larynx and thyroid gland.



**Figure 78-11, cont'd** Modified neck dissections, preserving the IJV and the 11th nerve (C) and the 11th nerve, the IJV, and the SCM. (D)

## RADIOLOGIC STAGING

Radiologic evaluation is not a prerequisite for the performance of neck dissection in most cases of cancer of the head and neck. Nevertheless, suspicious nodes may be identified in regions in which removal had not been previously contemplated. Preoperative imaging is becoming standard in the preoperative evaluation of

these patients in most centers, with criteria for determination of node positivity demonstrated in Figure 78-12. Computed tomography (CT) increases the accuracy of visual examination of the neck by 10% to 15% but is still less than 100% reliable.<sup>17</sup> A negative CT scan should not lull the surgeon into complacency regarding the possibility of occult metastatic nodes.

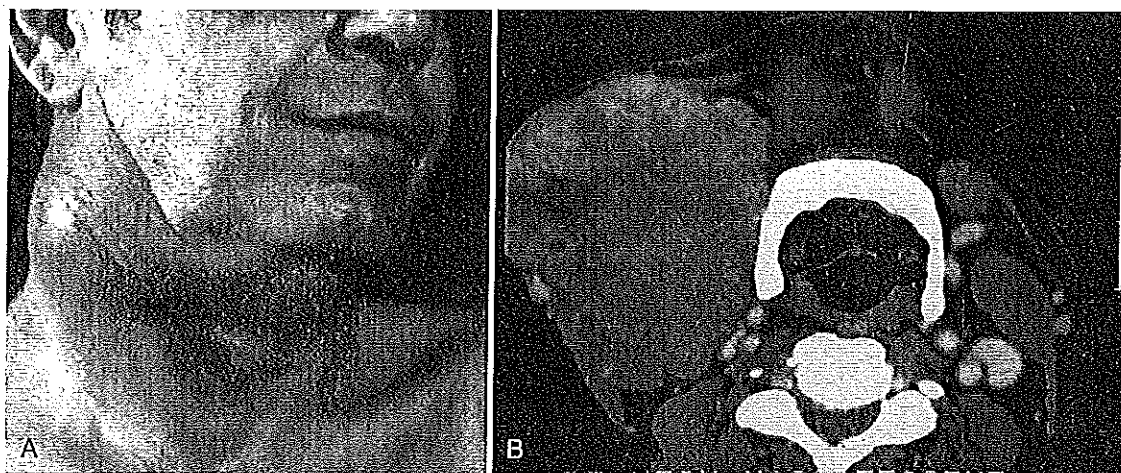
The use of MR scanning is standard in some institutions, although many surgeons find MR scan to be more difficult to interpret than CT scan. A multi-institutional trial comparing MR with CT scan demonstrated no significant benefit of one modality over the other.<sup>17</sup> Positron emission tomography (PET)/CT scanning is becoming a commonly used tool in the evaluation of patients with unknown primary cancers of the head and neck as well as of patients with extensive disease. Due to the requirement of a sizable deposit of metastatic disease to facilitate imaging, PET/CT is not as useful in the evaluation of the clinically negative neck—an indication that is primarily investigational as of this time.

## PATIENT SELECTION

Surgical decision making for patients with head and neck cancer has become more challenging over the past decade with advances in nonoperative therapy. Organ preservation treatment protocols often yield survival rates similar to those of surgical management, typically with improved postoperative function for affected patients. Treatment of these patients usually includes management of the neck with nonoperative therapy concomitant with the treatment of the primary tumor. Treatment decisions for patients who have persistent evidence of neck disease following nonoperative therapy is not difficult, because salvage neck dissections are well tolerated and offer a survival benefit. Pathologic examination of the surgical specimens may not demonstrate viable tumor in up to 50% of these cases, but in the absence of preoperative certainty, surgery is indicated. PET/CT imaging may alter decision making in some of these patients.

More problematic is decision making for the patient with advanced neck disease (N2-3) who has demonstrated significant response to organ preservation therapy. Opinions are split,<sup>18-20</sup> although it would appear that apparently persistent viable tumor can be seen on histologic examination in approximately 20% to 30% of specimens. What is not clear, however, is the extent of the risk of continued tumor proliferation. It seems likely that this group of patients stands to benefit the most from routine posttreatment PET/CT imaging.

Selection of the appropriate surgical procedure for the management of the cervical nodes in a particular patient is based on multiple factors, including the primary site of the cancer, patient status, prior therapy, and treatment goals. The radical neck dissection, or modifications thereof, is preferred for advanced stage neck disease that is technically resectable. Identification of patients with technically unresectable advanced neck disease is a difficult clinical problem, even with the advent of CT and magnetic resonance imaging. Encase-



**Figure 78-12.** A, A patient with a massive right neck mass that is metastatic from a piriform sinus carcinoma. B, Axial computed tomography scan of the neck of the patient in A. The scan demonstrates enlarged nodes with central necrosis and obscured nodal margins, criteria for malignancy.

ment of the internal carotid artery (Fig. 78-13) is usually a contraindication to neck dissection unless the surgeon is prepared to resect and graft the carotid artery and the patient has been evaluated to determine the consequences of this procedure. Newer techniques to identify patients with adequate cerebral blood flow after unilateral radical neck dissection with carotid sacrifice may be used to select a subset of patients with carotid involvement who would tolerate carotid excision without suffering unacceptable central nervous system compromise. Unfortunately, long-term outcomes in this group of patients are uniformly poor except in rare instances in which other structures are not involved by tumor. Similarly, patients with a mass in the neck attached to the deep cervical musculature are usually not considered candidates for radical neck dissection.

Modifications of the radical neck dissection may be appropriate for use in patients with palpable neck disease. Preservation of the 11th nerve is the most common modification, and preservation of the jugular vein is also common. Preservation of the SCM is more problematic due to the difficulty in dissecting level V during a comprehensive modified neck dissection while leaving the SCM intact.

Selective neck dissections remove selected groups of nodes at greatest risk of involvement. These procedures are used for the management of patients without palpable neck nodes but who are at risk for occult nodal disease. Because not all nodal groups are removed, these operations are tailored for individual patients. Often their primary value is as a staging procedure, although they may, in fact, be therapeutic for this group of patients in that the nodes removed are those most likely to contain microscopic cancer.<sup>21</sup> Selective neck dissections are best suited for patients without clinical evidence of metastatic disease or with small, single, mobile nodes:

Cancer in certain primary sites has a high propensity for bilateral nodal involvement. We have demonstrated lower levels of recurrence in the neck following

bilateral, vein-preserving surgical procedures in selected sites such as the supraglottic larynx<sup>1</sup> and hypopharynx.<sup>22</sup> In our experience, radiation therapy administered postoperatively in adjuvant doses has not been effective in sterilizing necks containing occult metastatic disease. For this reason, we recommend bilateral selective neck dissections for primary squamous cell cancer of selected sites when surgery is selected as primary therapy.

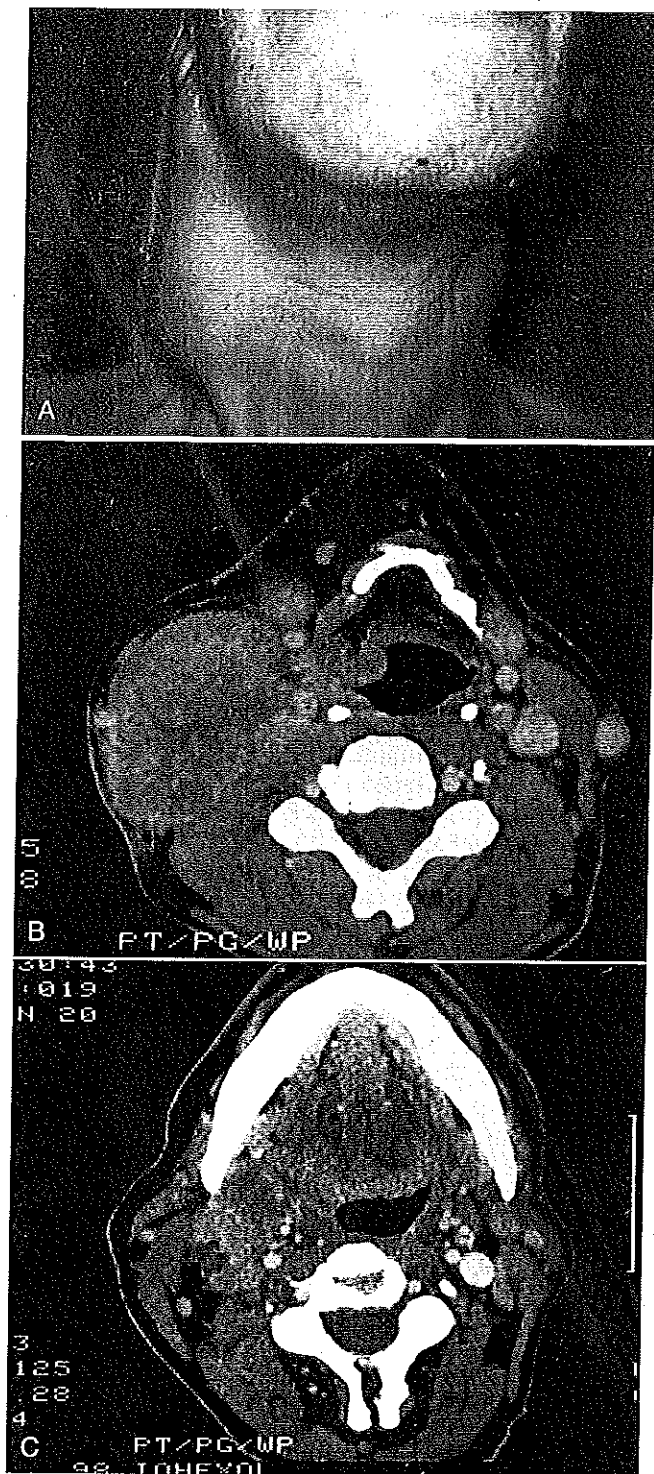
Perhaps the most significant advantage to selective neck dissection is the histologic staging information provided. Identification of a subset of patients with advanced disease or with disease with poor prognostic signs, such as the presence of multiple positive nodes or nodes with ECS of tumor, enables selective use of adjuvant radiotherapy and, in some patients, chemotherapy.

If the neck dissection specimen contains no involved nodes or only one or two small nodes without ECS of tumor, adjuvant therapy may not be necessary. Single-modality therapy may significantly decrease morbidity and enhance the results of postoperative rehabilitation.

For these as well as other reasons (e.g., surgical access), we believe that selective neck dissection should be considered routine in the management of squamous cell cancer in selected patients who have no clinically palpable nodes.

## PREOPERATIVE PLANNING

Patient selection is the most critical portion of preoperative planning. An assessment of the patient's disease, comorbidities, and treatment goals is required. Management of underlying medical diseases will usually mandate close cooperation with medical consultants. Patients who present with significant weight loss and hypoalbuminemia will fail to heal, and preoperative nutritional support is required. In most instances, this will require the placement of a nasogastric or gastrostomy tube. Nutritional status is particularly problematic



**Figure 78-13.** Photograph (A) and axial computed tomography (CT) scans (B and C) of the neck of a patient with massive cervical lymphadenopathy. The CT scans demonstrate encasement of the left carotid artery and suggest tumor invasion of the sternocleidomastoid muscle and the deep cervical muscles.

in the group of patients who present for salvage neck dissection following nonoperative therapy. Although prior chemotherapy does not adversely affect wound healing, the depleted nutritional status of the patient does. There is consensus that prior radiotherapy affects

wound healing, although the primary effect may be the severity of wound complications rather than the actual incidence for most patients.

Preoperative planning includes obtaining informed consent from the patient. It is appropriate to explain to the patient why a neck dissection is being performed and any alternative forms of therapy. It is probably appropriate to note that radiation therapy may be able to control 80% to 90% of disease-free necks but does not provide the pathologic staging information that a neck dissection does. Radiation therapy may, in the long run, have more significant long-term complications than selective or modified neck dissection (or for that matter, the classic radical neck dissection). Withholding radiation therapy when other options are available may permit its use later in the treatment of second primary cancers. We reserve radiation therapy for patients treated with nonoperative organ preservation protocols or for those with biologically advanced disease who require adjuvant therapy. Radiotherapy is not routinely offered as an alternative treatment for the disease-free neck, except when the primary tumor is managed with radiotherapy.

Perioperative antibiotics are required in the preoperative period if the procedure will involve going through the neck into the upper aerodigestive tract. There may be an advantage to the use of antibiotics in noncontaminated cases as well; Carrau and associates demonstrated a risk of postoperative wound infection of 10% in this population.<sup>23</sup>

## SURGICAL TECHNIQUES

The technique of neck dissection varies with the location of palpable disease, the planned procedure for the primary tumor, and the type of neck dissection. The techniques are divided into the comprehensive neck dissections (with the classic radical neck dissection and its modifications) and the selective neck dissections.

Identification of a sequence for a surgical procedure is a valuable adjunct to the resident in learning the techniques used in a specific operation. Perhaps this is most important in the performance of a neck dissection because an orderly sequence of events will result in the identification and preservation of vital structures and ensure the safety as well as the expediency of the procedure. Tables 78-1 and 78-2 list the sequences of the operative procedures we perform for the radical and modified radical neck dissections and selective neck dissection. The exact sequence used by the operating surgeon may vary. However, reviewing this sequence or keeping it on a 3 × 5 note card for preoperative reference will be valuable to the resident and the infrequent operator.

## RADICAL NECK DISSECTION

Radical neck dissection was standardized in the years following its first description by Crile in 1906.<sup>5</sup> Interestingly, in his initial diagrams, Crile indicated routine preservation of uninvolved structures such as the SCM

**Table 78-1 STEPS IN RADICAL NECK DISSECTION**

Perioperative antibiotic?
Position on shoulder roll
Prepare and drape (staples)
Incision
Avoid trifurcation over carotid
Avoid narrow flaps
Incise through platysma
Raise subplatysmal flaps
Leave greater auricular nerve and external jugular vein on sternocleidomastoid muscle (SCM)
Identify/preserve marginal mandibular nerve
Level I dissection
Remove submandibular nodes and submandibular gland
Ligate facial artery above digastric muscle
Include submental fat pad
Expose anterior border of trapezius muscle
Incise SCM 1 to 2 cm above clavicle
Identify and trace omohyoid
Transect omohyoid posteriorly
Bluntly dissect and identify brachial plexus and phrenic nerve
Bluntly dissect and transect posterior triangle
Incise along anterior border of trapezius
Incise superior end of SCM
Rotate specimen anteriorly
Re-identify and preserve brachial plexus, phrenic nerve
Identify cervical nerves and incise <i>high on specimen</i>
Identify carotid (and vagus)
Return neck specimen to anatomic position and identify, cut, and ligate inferior jugular vein
Do not incise vagus nerve!
Re-identify phrenic and vagus nerves; then clamp, cut, and ligate lymphatic pedicle to avoid chyle leak
Elevate specimen from carotid and vagus, proceeding superiorly
Identify and preserve hypoglossal nerve
Ligate superior jugular vein at the digastric muscle
Rotate specimen anteriorly
Ligate ranine veins
Preserve superior thyroid artery and superior laryngeal nerve
Resect specimen with anterior cervical veins and fascia
Irrigate wound
Ensure hemostasis
Insert drains
Close wound
Pressure dressing

**Table 78-2 STEPS IN SELECTIVE NECK DISSECTION**

Raise subplatysmal flaps
Leave external jugular and greater auricular nerve on sternocleidomastoid muscle (SCM)
Posterior elevation not necessary
If level I dissection:
Identify and preserve marginal mandibular nerve
Expose anterior belly of digastric muscle
Expose mylohyoid muscle
Elevate mylohyoid muscle
Identify lingual, hypoglossal nerves
Divide duct, vessels
Resect submaxillary gland
Identify posterior belly of digastric muscle
Identify posterior digastric muscle (Under submaxillary gland if not level I)
Follow posterior digastric muscle to SCM
Incise SCM fascia, including external jugular vein and external jugular greater auricular nerve
Unwrap SCM
Peel muscle from fascia
Identify accessory nerve
Trace accessory nerve to digastric muscle
Lift accessory nerve
Free posterior corner
Watch internal jugular vein and 11th nerve
Pass posterior corner under accessory nerve
Cut deep fascia to omohyoid muscle
Identify, trace cervical nerves
Protect plexus and phrenic nerve
Identify carotid sheath
Unwrap fascia from internal jugular vein
Go slow
Identify, ligate branches of internal jugular vein
Elevate, clamp, ligate lymphatic pedicle
Watch for vagus, phrenic nerves
Follow omohyoid muscle, carotid artery, internal jugular vein
Preserve superior thyroid artery and hypoglossal nerve
Divide ranine veins
Label specimen—then:
Resect specimen

and 11th nerve. En bloc resection became standard in the ensuing years. Incisions that were used in early years placed the carotid artery at risk by placing trifurcation points over the artery. Current wisdom dictates that incisions be fashioned so as to avoid narrow flaps and avoid trifurcation points placed over the internal carotid artery. An extended apron incision is used for laryngectomy, although a posterior extension may be necessary to gain access to the posterior portion of the dissection. In our department we use a "hockey stick" incision for unilateral or an apron flap for bilateral neck dissection (Fig. 78-14).

Skin incisions are made and flaps are elevated in the subplatysmal plane. When elevating the superior flap, it is wise to leave the external jugular vein and GA

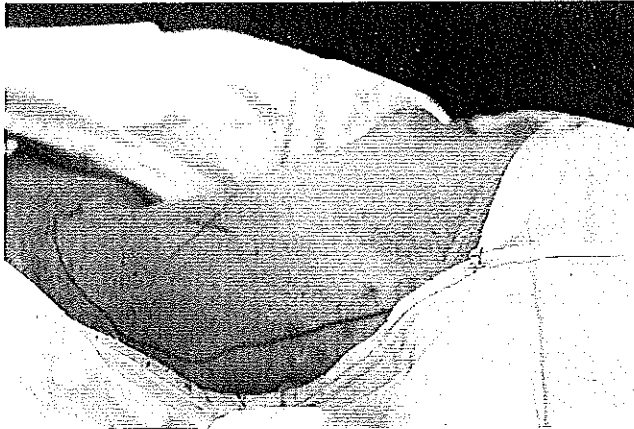


Figure 78-14. The "hockey stick" incision is used for unilateral radical or elective neck dissection.

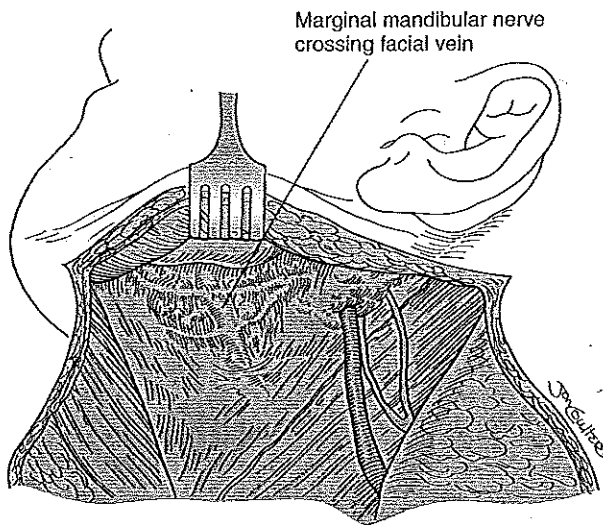


Figure 78-15. Identification of the marginal mandibular nerve (arrow) where it crosses the facial artery and vein. Note the proximity of the prevascular and postvascular nodes to the nerve.

nerve on the SCM (Fig. 78-15). At the superior aspect of the flap, the marginal mandibular nerve is identified approximately 1 cm anterior to the angle of the mandible where it crosses lateral to the submandibular gland and facial vessels (Fig. 78-16). Injury can best be avoided by identifying the nerve, dissecting anteriorly and posteriorly, and then elevating the nerve as part of the skin flap. Retraction of the nerve superiorly by suturing the divided facial vessels to the flap will help in protecting the nerve through the remainder of the procedure. There are frequently several branches of the nerve, of which the superior is the most important in preservation of lip function. Once the correct plane is identified, all branches can often be elevated simultaneously. Obviously, if the marginal branch is involved with or close to a metastatic node, it must be sacrificed.

It is often easiest to proceed with the submandibular (level I) dissection at this point in the procedure. Some surgeons routinely remove the nodes in level I at

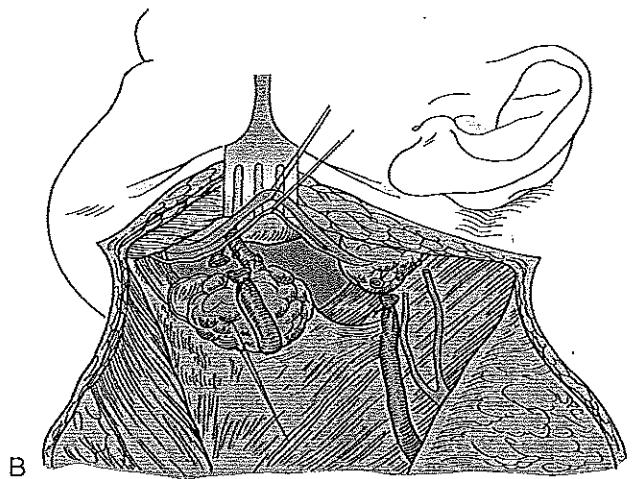
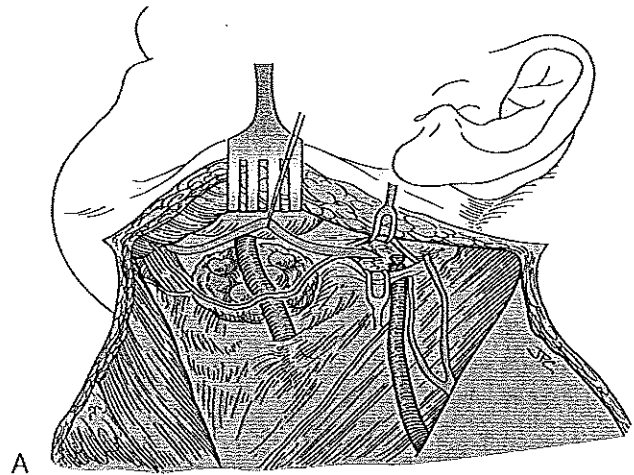
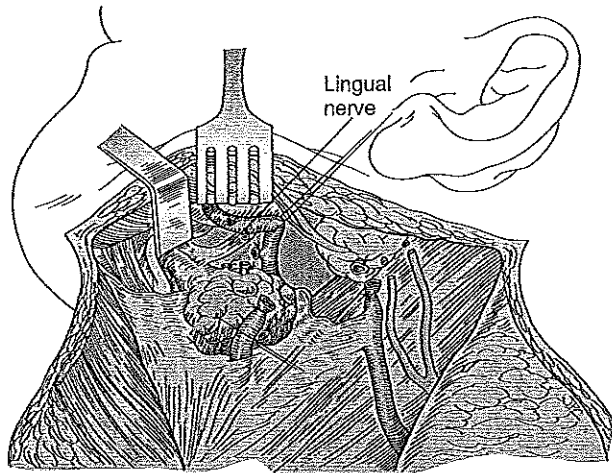


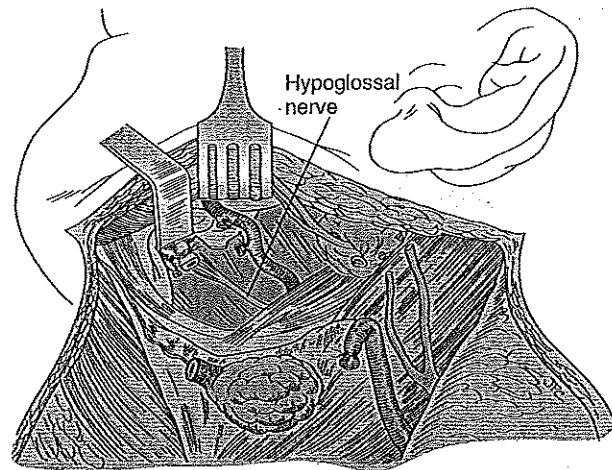
Figure 78-16. Dissection of the marginal mandibular nerve from the submandibular gland posteriorly in order to preserve the nerve. Note that all branches of the greater auricular nerve have been divided in this illustration. In practice, the posterior branch can usually be preserved.

this point, whereas others perform the level I dissection at the completion of the remainder of the neck dissection.

The submandibular gland and surrounding nodes are removed en bloc as a level I dissection. The procedure is begun by incising the fascia above the gland and identifying the anterior belly of the digastric muscle, clearing the submental fat pad, and elevating the fascia and nodes from the lateral surface of the mylohyoid muscle (Fig. 78-17). The lateral superior fascia and vessels were divided earlier when the marginal nerve was identified. Care must be taken to include the submental fat pad in the specimen, which is performed by grasping the fat pad just medial to its attachment to the anterior belly of the digastric muscle and dissecting the midline tissue in the submental triangle in an inferior direction. The mylohyoid muscle is then retracted anteriorly, exposing the lingual nerve and submandibular ganglion (Fig. 78-18). The attachments of the gland to the lingual nerve at the submaxillary ganglion are



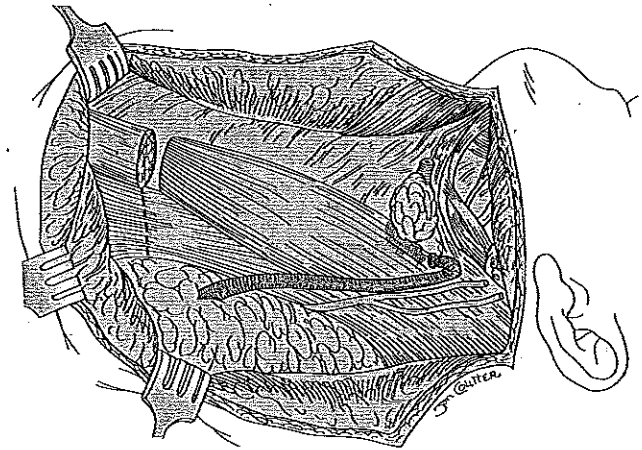
**Figure 78-17.** Retraction of the mylohyoid muscle to expose the lingual nerve, submandibular ganglion, and Wharton's duct.



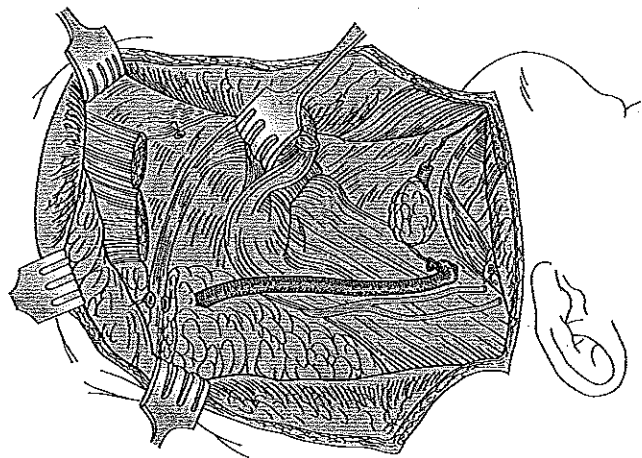
**Figure 78-18.** Ligation of the submandibular duct. Note the preservation of the lingual nerve and the hypoglossal nerve. Preservation of the facial artery is optional and is usually not difficult.

divided and ligated, and the submandibular duct is divided and ligated. The gland is retracted inferiorly with the attached prevascular nodes on its lateral surface. Leaving the fascia attached to the submandibular gland inferiorly will allow the contents of level I to remain a part of the neck dissection specimen. The facial artery may be preserved as shown in Figure 78-18.

The posterior skin flap must be elevated toward the trapezius muscle in the appropriate plane at the level of the platysma. Because the platysma is deficient in this region, it is not difficult to inadvertently dissect too deeply and injure the 11th nerve by dissecting under the trapezius. By grasping the edge of the skin flap with Lahey clamps and using a finger placed behind the incision, the depth of dissection can be determined to avoid nerve injury and buttonholing of the flap. Identification of the anterior border of the trapezius is a key point in this procedure. The anterior border of this



**Figure 78-19.** Division of the inferior end of the sternocleidomastoid muscle, about 1 fingerbreadth above the clavicle.



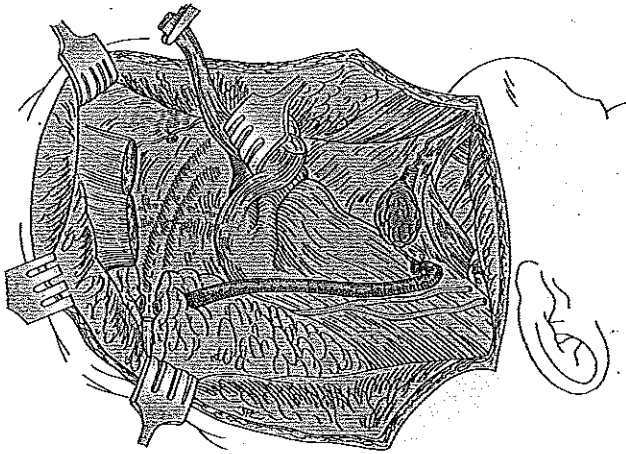
**Figure 78-20.** Dividing the clavicular head of the sternocleidomastoid muscle and supraclavicular tissue lateral to the omohyoid muscle. The brachial plexus, carotid sheath, and phrenic nerve are protected by their position deep to this muscle.

muscle is usually more posterior and superficial than expected. Stimulation of the 11th nerve can assist in identification of the muscle.

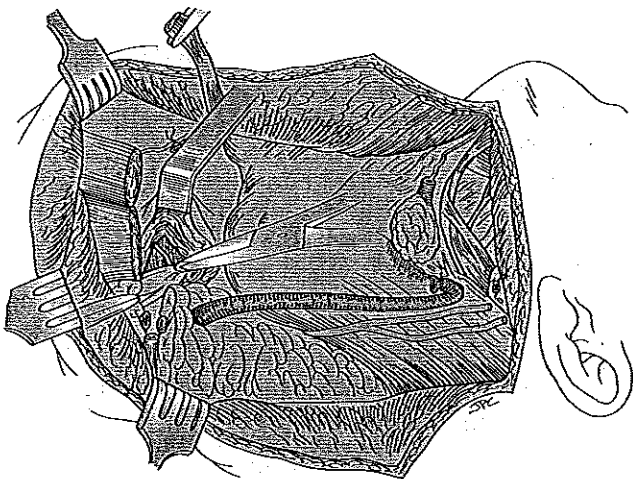
If a modified neck dissection is being performed, this is an ideal time to identify the 11th nerve and trace it through the posterior portion of the neck to the trapezius and SCM (see Fig. 78-5). If a radical neck dissection is being performed, the sternal head of the SCM is divided approximately 1 fingerbreadth above the clavicle (Fig. 78-19). There is one bleeder in the stump that must be clamped. The clavicular head is also transected just above the clavicle, taking care not to cut the external jugular vein, which is just posterior and lateral to the inferior portion of the muscle (Fig. 78-20). Once the SCM is divided inferiorly, the omohyoid is easily identified where it crosses the IJV. It is often appropriate to extend the superficial fascial incision anteriorly through the anterior jugular veins, which are ligated at this point.

The omohyoid is followed posteriorly. Nerves, vessels, and fascia lateral to the muscle can be incised without risk of injury to significant structures. Several large veins in the region will require ligation (see Fig. 78-20). The fascia over the omohyoid muscle is then elevated anteriorly to the midline. This identifies the anterior extent of the neck dissection. The omohyoid is divided posteriorly as it approaches the scapula. Electrocautery is useful here to avoid retraction of a bleeding muscle stump. The fascia immediately deep to the posterior belly of the omohyoid muscle is then divided (Fig. 78-21).

The supraclavicular fat pad is then opened using blunt dissection, exposing the brachial plexus and phrenic nerve (Fig. 78-22). Identification of the brachial plexus is critical, and the procedure should not be continued until both the brachial plexus and the phrenic nerve (located on the surface of the anterior scalene muscle) have been identified. The transverse



**Figure 78-21.** Division of the omohyoid muscle posteriorly and exposure of the brachial plexus. The fascia deep to the omohyoid muscle is divided.

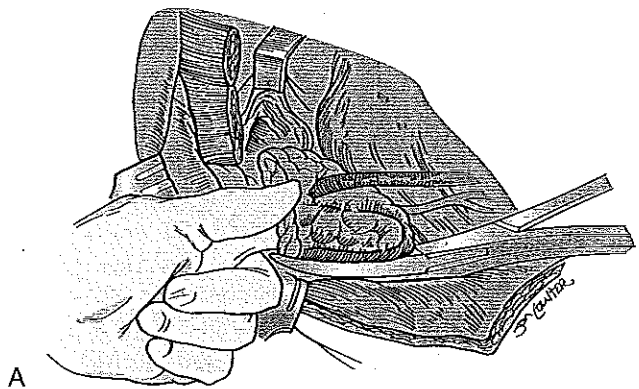


**Figure 78-22.** Nerve trunks of the brachial plexus are visualized with blunt dissection. The phrenic nerve can be seen just anterior, crossing the anterior scalene muscle.

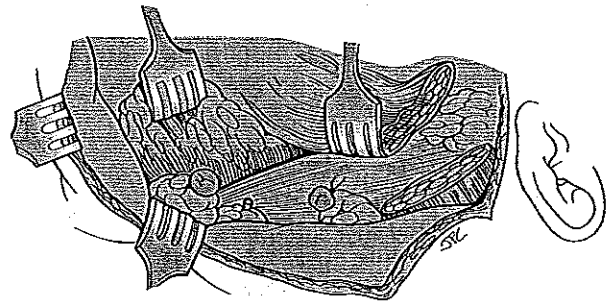
cervical artery and vein will be found immediately adjacent to the phrenic and will extend posterior in a plane just lateral to the brachial plexus. In order to avoid troublesome bleeding, care should be taken not to interrupt the vessels. The surgeon must be cautious in avoiding elevation of the phrenic nerve from its position on the surface of the anterior scalene muscle or it can easily be inadvertently divided later in the procedure. Excessive electrocautery near the brachial plexus and phrenic nerve is to be avoided.

Once the brachial plexus and phrenic nerve have been identified, finger dissection can be performed posteriorly toward the anterior border of the trapezius, and the supraclavicular fat pad can be divided between clamps and suture ligated (Fig. 78-23). Attempting to perform this dissection without ligation will usually result in troublesome bleeding. Some surgeons use a gastric stapler for this portion of the procedure.

Dissection is carried superiorly along the anterior border of the trapezius to the level of the SCM. If the 11th nerve has been preserved, care must be taken at this point to avoid injury to the nerve; alternatively, if a radical neck dissection is being performed, the nerve is resected as part of a specimen. The superior end of the SCM is then divided just inferior to the mastoid tip. Retractors are placed on the specimen, and it is rotated



A



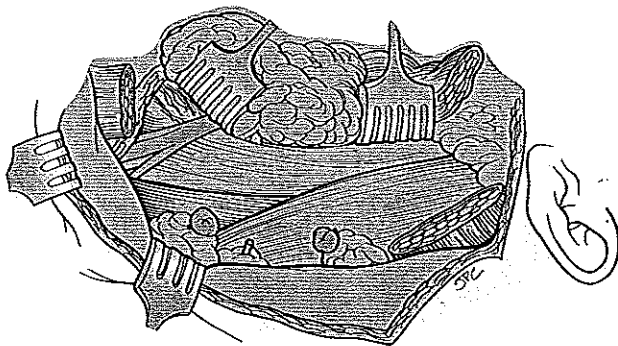
B

**Figure 78-23.** A, Exposure of the anterior border of the trapezius muscle and division of the fatty lymphatic structures. Once the brachial plexus is visualized, blunt dissection with a finger permits clamping of the fibrofatty tissue with large clamps. The 11th nerve is sacrificed, if required. Otherwise, it is elevated and the specimen is dissected from underneath. B, Dissection is carried superiorly, and the superior head of the sternocleidomastoid muscle is divided.

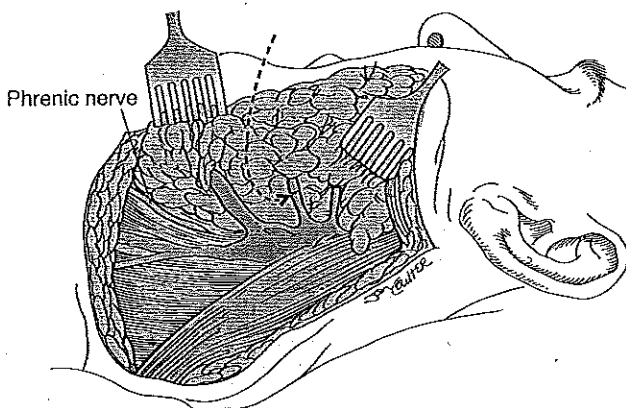


anteriorly (Fig. 78-24). The dissection is then carried anteriorly. It is helpful to leave the fascia on the deep muscles to protect the neural supply to the levator scapulae muscle as well as the roots of cervical plexus. It is critical to avoid dissecting the cervical plexus off the deep muscles or the roots will be interrupted.

Once the nerves exiting the cervical plexus have been encountered, they are traced for a short distance into the specimen and then divided (Fig. 78-25). It is important to visualize the phrenic nerve during this portion of the procedure in order to avoid inadvertent severance of the contributions from the cervical plexus. Dissection is carried laterally into the fatty tissue of the specimen, and the nerves are sectioned, leaving approximately 1 cm of nerve attached to the cervical plexus. Accompanying vessels will require ligation, and it is easiest to apply a hemostat to the nerves before sectioning. Electrocautery should be avoided in this region to prevent injury to the brachial plexus and phrenic nerve. Care must be taken to preserve the cervical rootlets where they exit between the middle and the anterior scalene muscles medial to the cervical plexus and phrenic nerve. Resection of the cervical plexus or interruption of its roots is a serious error in technique that



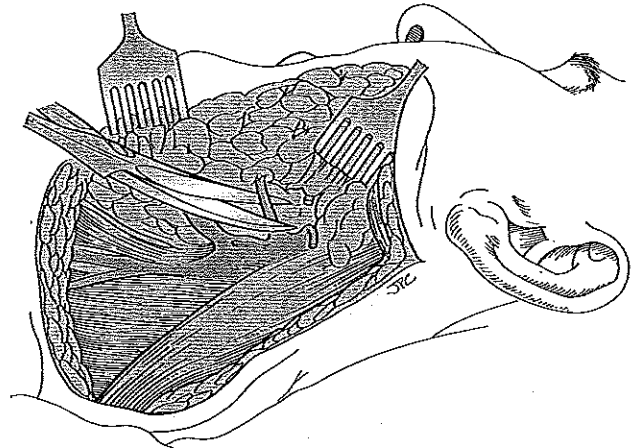
**Figure 78-24.** Division of the superior head of the sternocleidomastoid muscle permits the specimen to roll anteriorly, exposing the deep cervical muscles. Dissection is carried anteriorly from this point.



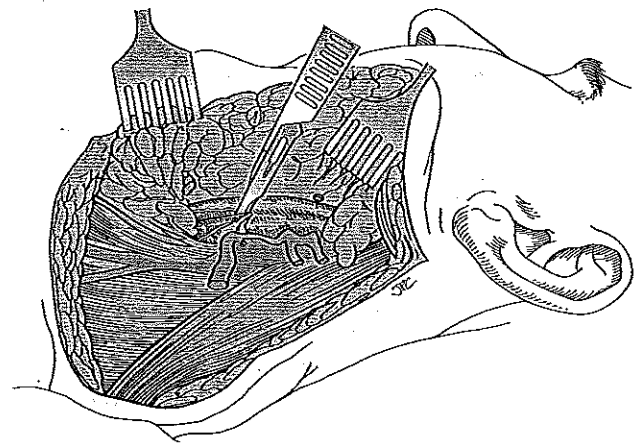
**Figure 78-25.** Exposure of the cervical nerves as they leave the cervical plexus. Care must be taken to avoid stripping the cervical plexus off the deep muscles.

can be avoided by leaving a thin layer of fascia on the deep muscles and by cutting the nerves *after* they leave the plexus (Fig. 78-26).

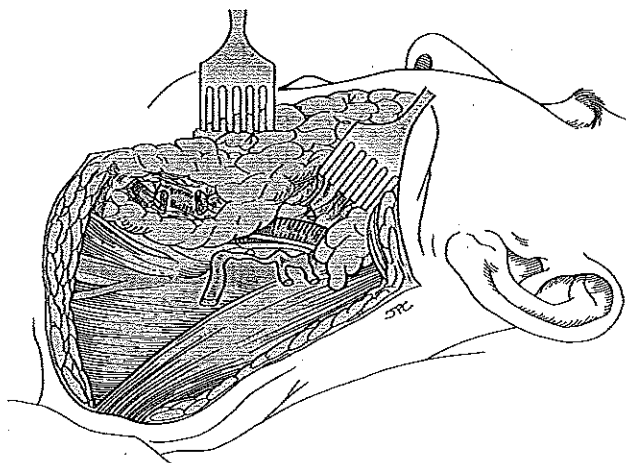
Once the cervical nerves have been divided, the carotid sheath is encountered from posterior. Finger palpation is useful at this stage. Care must be taken not to dissect medial to the carotid sheath to avoid injury to the cervical sympathetic chain. The jugular vein, carotid artery, and vagus nerve can then be identified and the structures dissected from the posterior belly of the digastric muscle superiorly to 3 to 4 cm above the clavicle inferiorly (Fig. 78-27). Extending the dissection too far inferiorly at this point in the procedure, particularly on the left side, may result in injury to the thoracic duct and postoperative chyle leak. To avoid this complication, the lymphatic pedicle should be isolated and clamped and divided en bloc. This can be facilitated by reflecting the neck tissue back into its anatomic position, exposing the jugular vein from anterior approximately 2 cm above the clavicle, and then dividing the vein (if resection is planned) between Kelly clamps (Fig. 78-28). Tearing the tributaries of the vein during



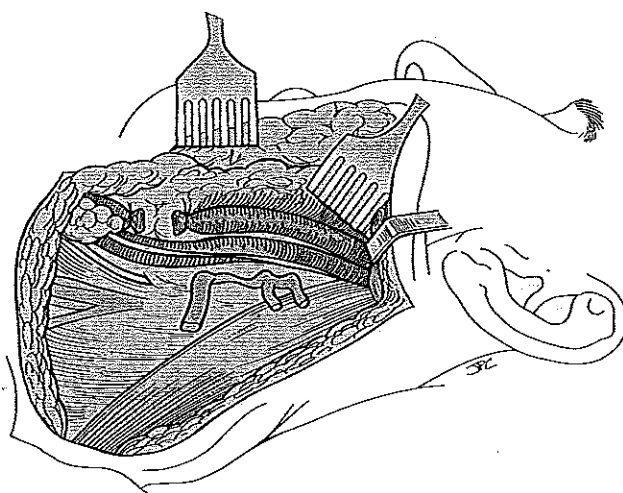
**Figure 78-26.** The cervical nerves are incised at least 1 cm distal to the plexus to avoid inadvertent injury to the phrenic nerve.



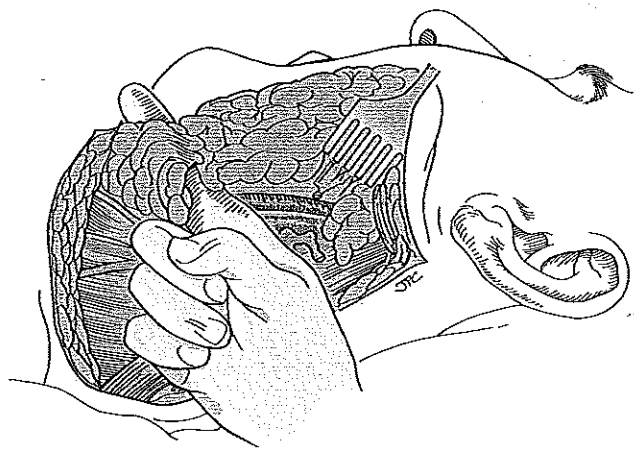
**Figure 78-27.** Exposure of the carotid sheath. Care is taken to avoid extending the dissection too far inferiorly on the left side to avoid injury to the thoracic duct.



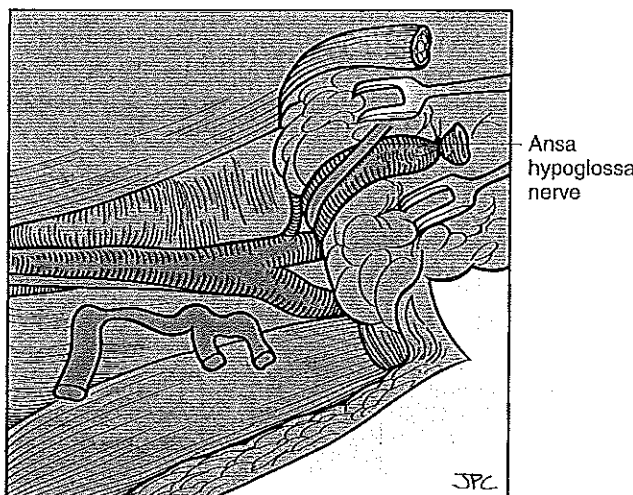
**Figure 78-28.** Division of the internal jugular vein before dividing and ligating the lymphatic pedicle. This is best done by reflecting the neck tissue back into its anatomic position and freeing the vein from anteriorly.



**Figure 78-30.** Division and ligation of the lymphatic pedicle frees the inferior portion of the specimen.



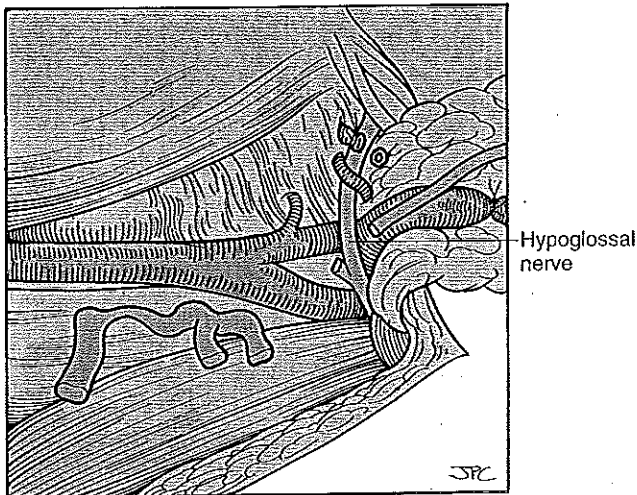
**Figure 78-29.** Isolation of the lymphatic pedicle. The carotid sheath structures are identified and a finger is passed through the tunnel created. Care must be taken to avoid entrapping the phrenic or vagus nerve. Once all structures have been positively identified, the pedicle is clamped and ligated en bloc.



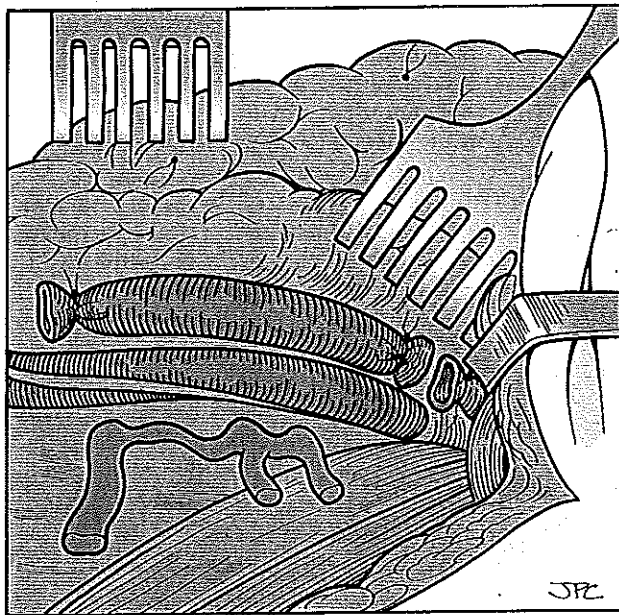
**Figure 78-31.** Elevation of the specimen from inferior to superior with the internal jugular vein and the ansa hypoglossal nerve.

dissection can result in troublesome bleeding. If the surgical plan includes leaving the jugular vein intact, the fascia can be freed from the jugular vein and its tributaries divided. If the jugular vein is resected, it is customary not only to ligate the vein but also to apply a suture ligature to prevent the ligature from slipping off. Care must be taken to avoid dividing the vagus nerve or common carotid artery. The vagus nerve should be identified as it courses immediately adjacent to the carotid artery before dividing either the jugular vein or the lymphatic pedicle. Following ligation of the vein or dissection, a finger is placed around the lymphatic pedicle (Fig. 78-29), and following identification of the phrenic nerve and vagus nerve, the pedicle can be clamped, divided, and suture ligated (Fig. 78-30). At this point, it is wise to ask the anesthesiologist to temporarily provide positive pressure in order to ensure that there is no evidence of a chyle leak.

The dissection is then continued in an inferior-to-superior direction along the carotid artery and vagus nerve. The ansa cervicalis is elevated and divided, as is the ansa hypoglossi (Fig. 78-31). Following the ansa hypoglossi superiorly will help in identifying the hypoglossal nerve, which must be preserved unless it is involved with tumor (Fig. 78-32). The ranine veins will require individual ligation, with care taken to avoid injury to the hypoglossal nerve. The IJV is divided superiorly at the level of the posterior belly of the digastric muscle. In the absence of tumor mass superiorly, an alternative approach is to divide the vein at the posterior belly of the digastric muscle before ligating it inferiorly. The vein is usually best approached from posterior and lateral, transecting the accessory nerve, identifying the digastric muscle and retracting it superiorly, and then dividing and ligating the IJV (Fig. 78-33).



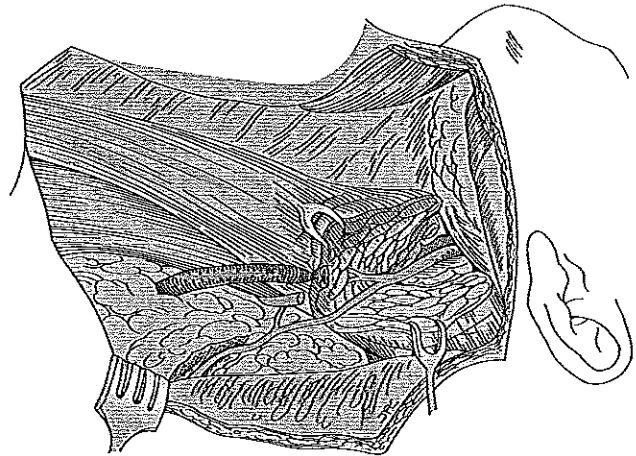
**Figure 78-32.** Identification of the hypoglossal nerve. Note the ansa hypoglossal nerve, which can assist in identification of the hypoglossal nerve. Care must be taken to avoid injury to the nerve while clamping the often troublesome ranine veins, which form a plexus around the nerve.



**Figure 78-33.** Division of the internal jugular vein at the digastric muscle.

As the dissection is carried along the carotid artery, it may become necessary to inject lidocaine without epinephrine into the adventitia over the carotid bulb if bradycardia and hypotension occur from stimulation of the carotid pressure receptors. At this point, the dissected specimen is attached only at the level of the hyoid bone and is easily removed. If it was not done initially, the level I dissection is performed at this time, and the specimen is removed.

Hemostasis is obtained, the wound is irrigated, and drains are inserted. The incision is closed in layers, with care being taken to approximate the platysma muscle



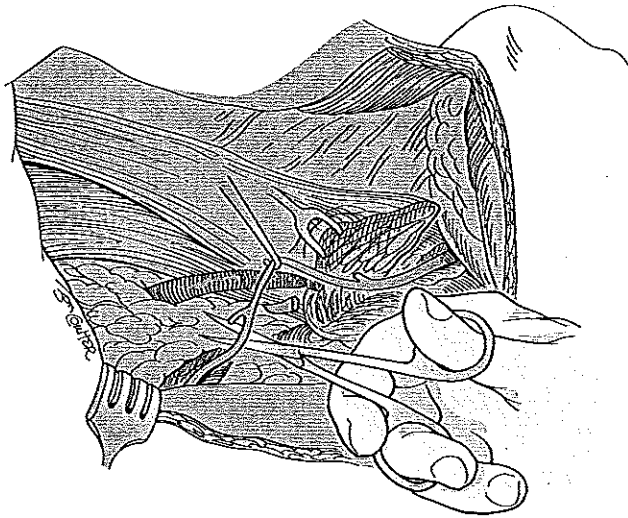
**Figure 78-34.** Identification of the 11th nerve in the posterior triangle and dissection through the sternocleidomastoid muscle to expose the 11th nerve from the trapezius to the digastric muscles.

by absorbable sutures to avoid unsightly postoperative scar retraction. Suction drains are used routinely, as is a circumferential dressing unless bilateral neck dissections are being performed or a pedicled muscle flap has been used for reconstruction.

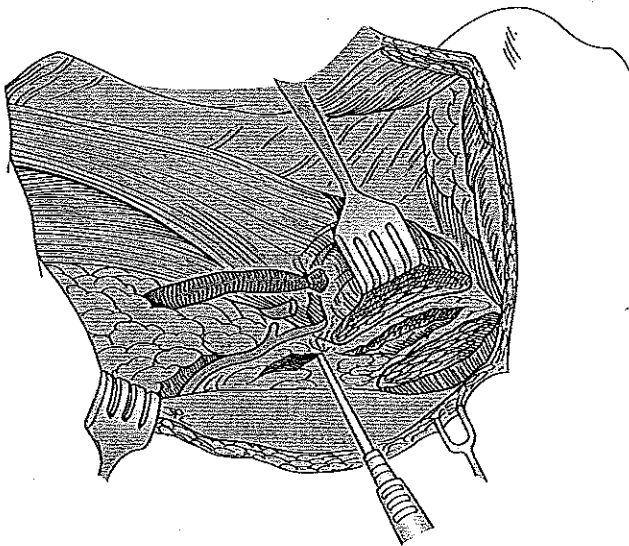
## MODIFIED NECK DISSECTION

Various modifications of the radical neck dissection are used. If the SCM is to be preserved, the procedure is usually begun in the same manner as for a selective neck dissection by freeing the SCM and the 11th nerve. The node-bearing tissue in level V is then passed under the elevated SCM, and the dissection is completed. If the SCM is to be sacrificed, the procedure is begun as a radical neck dissection. The 11th nerve is identified in the posterior triangle and dissected free as it passes through the posterior triangle from the SCM to the trapezius muscle. The nerve is then dissected anteriorly through the substance of the SCM, effectively dividing the SCM into a superior and an inferior segment (Fig. 78-34). The branch of the accessory nerve to the SCM is divided and the nerve elevated (Fig. 78-35). From this point, the procedure is performed in a manner identical to a radical neck dissection, except that the incision along the anterior edge of the trapezius muscle does not include the 11th nerve but rather passes *under* the elevated nerve. Dissection is carried along the anterior border of the trapezius and across the insertion of the SCM in the manner of a radical neck dissection (Fig. 78-36), and the posterosuperior quadrant of the neck dissection is passed *under* the 11th nerve and then anteriorly (Fig. 78-37). If the IJV is to be preserved, the jugular vein is not divided but exposed from the posterior after the cervical nerves are divided. The vein is unwrapped in a manner similar to that for the selective neck dissection.

The modified comprehensive neck dissection is an ideal dissection for the therapeutic removal of clinically positive nodes when the 11th nerve and IJV can be



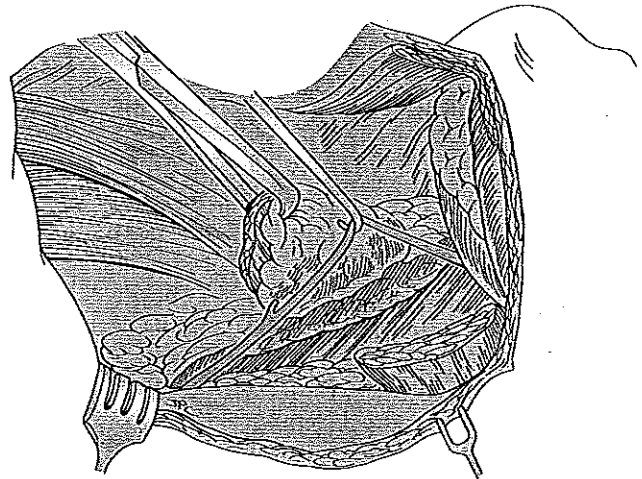
**Figure 78-35.** Elevation of the 11th nerve with division of the branch to the sternocleidomastoid muscle.



**Figure 78-36.** Incising the fibrofatty tissue anterior to the trapezius muscle and then across the insertion of the sternocleidomastoid muscle, as in a radical neck dissection.

safely preserved. A certain amount of surgical judgment is necessary, and immediate conversion to a radical neck dissection must be done if positive nodes are found adjacent to or infiltrate into the nerve or vein, making it oncologically unsafe to continue the modified procedure.

In cases of planned bilateral modified neck dissection, the contralateral neck is usually dealt with first in order to ensure preservation of the IJV, which is most likely to be preserved. If for technical or oncologic reasons the jugular vein on the contralateral neck has previously been removed or must be sacrificed, extra care should be taken to preserve the ipsilateral jugular vein if it is oncologically safe to do so. If both IJVs must be resected, we recommend venous reconstruction to decrease the risk of postoperative morbidity.



**Figure 78-37.** The posterosuperior portion of the specimen is passed under the elevated nerve.

## SELECTIVE NECK DISSECTION

Selective neck dissections begin in a manner similar to that for a radical neck dissection with elevation of skin flaps in the subplatysmal plane. When the selective neck dissection is used for the N+ neck, the platysma muscle is left on the specimen to provide an extra margin of resection. A utility incision (hockey stick) is generally used. The vertical limb is placed posterior to the SCM and the horizontal limb is placed in a skinfold above the clavicle in order to make the scar inconspicuous (Fig. 78-38). Dissection of the fascia from the SCM is facilitated by leaving the external jugular vein and GA nerve on the muscle (Fig. 78-39). If a level I dissection is planned as part of the procedure, the marginal mandibular nerve is identified and dissected free from the underlying vessels and nodes. It is reflected superiorly with the flap in a manner similar to that for the radical neck dissection. Identifying the marginal mandibular nerve and dissecting along it posteriorly to the parotid gland assists in incising the fascia posteriorly toward the SCM inferior to the parotid gland. If there is no need to remove the nodes in level I, identification of the marginal mandibular nerve is not necessary and the surgeon may identify the posterior belly of the digastric muscle under the submandibular gland and follow it posteriorly to the point at which it passes deep to the SCM (Fig. 78-40).

If removal of the contents of the submandibular triangle is planned, it is best performed at this time because dissection assists in the identification of the posterior belly of the digastric muscle. Following the identification, dissection, and elevation of the marginal mandibular nerve (see Fig. 78-16), the facial artery and vein may be ligated or preserved. The fascia over the gland is incised, and the anterior belly of the digastric muscle is exposed. The submental fat pad and nodes are dissected free and reflected inferiorly. The fascia is freed from the lateral surface of the anterior belly of the digastric muscle, and the mylohyoid muscle is

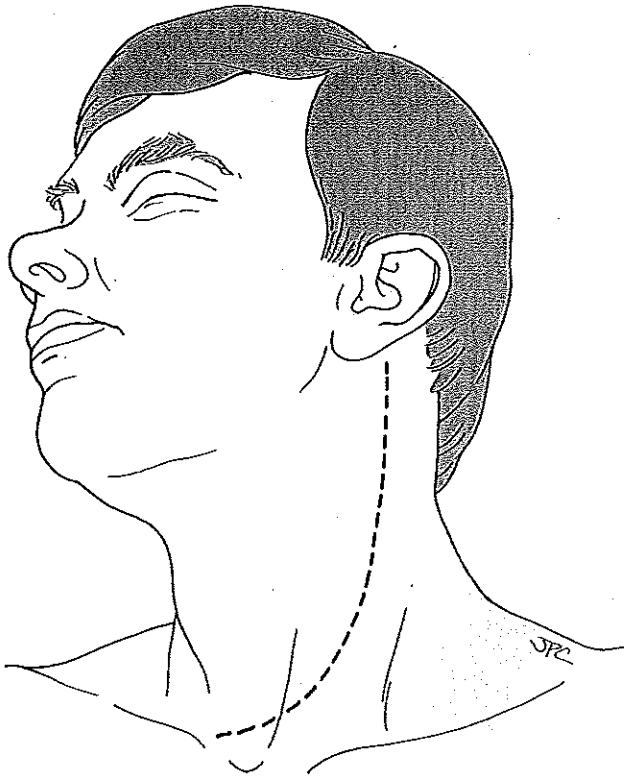


Figure 78-38. Utility incision or half-apron.

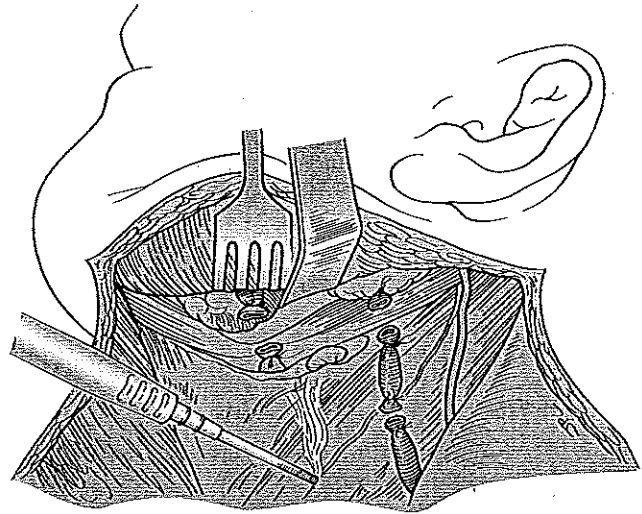


Figure 78-40. Identification of the corner formed by the posterior belly of the digastric muscle and the sternocleidomastoid muscle and the incision along the fascia of the SCM. The greater auricular nerve can generally be preserved, but the external jugular vein must be sacrificed.

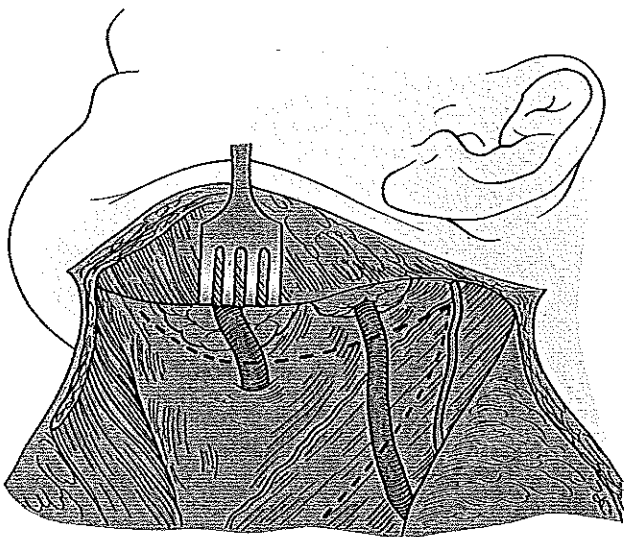


Figure 78-39. Line of the fascial incision if level I is not dissected.

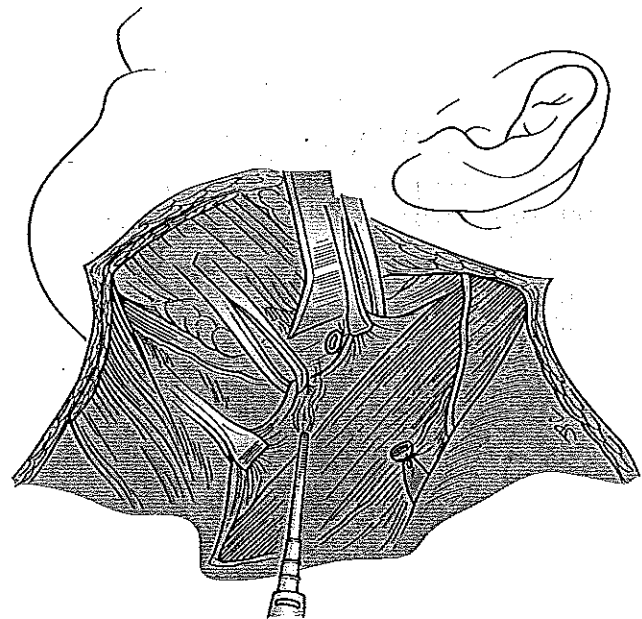


Figure 78-41. Unrolling the fascia from the muscle. In practice, it is easier to unroll the muscle from the fascia.

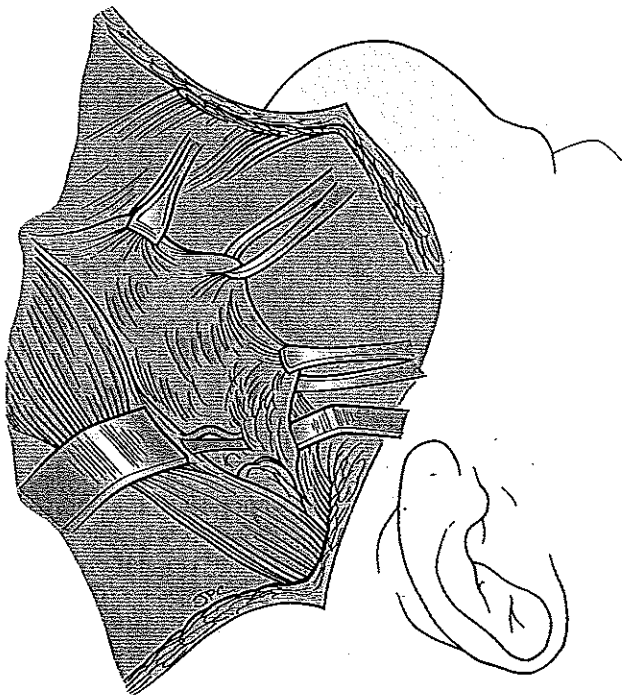
exposed. A significant number of vessels in this region require cautery for control, following which the posterior margin of the mylohyoid muscle is identified and retracted. Once the posterior edge of the mylohyoid muscle is retracted, the lingual nerve and its tributary to the submandibular gland can be identified (see Fig. 78-17), the tributary can be divided, and the subman-

dibular duct can be divided and ligated. Care must be taken to avoid injury to the 12th nerve, which lies deep to the fascia on the floor of the submandibular triangle (see Fig. 78-18). As the gland is reflected posteriorly and inferiorly, the facial artery is again encountered and either divided or preserved. This exposes the entire digastric sling and the posterior belly of the digastric muscle, which can be traced posteriorly to the point at which it passes deep to the SCM.

The fascia of the SCM with attached external jugular vein is then grasped, incised, and peeled from the muscle (see Figs. 78-40 and 78-41). If the GA nerve is

to be preserved, it should be dissected free at this time and retracted posteriorly. The posterior branch usually can be preserved, but must be elevated from the muscle to permit posterior retraction. Preservation of the anterior branch is technically more challenging. The fascia is grasped with Allis clamps, the muscle is retracted, and the fascia is unrolled from its attachment to the SCM utilizing either electrocautery or sharp dissection. This can usually be more easily performed by peeling muscle away from fascia rather than the reverse. The dissection is carried out on a broad plane extending from the region of the digastric muscle superiorly to the level of the omohyoid muscle inferiorly. The vessels entering the SCM are encountered and divided.

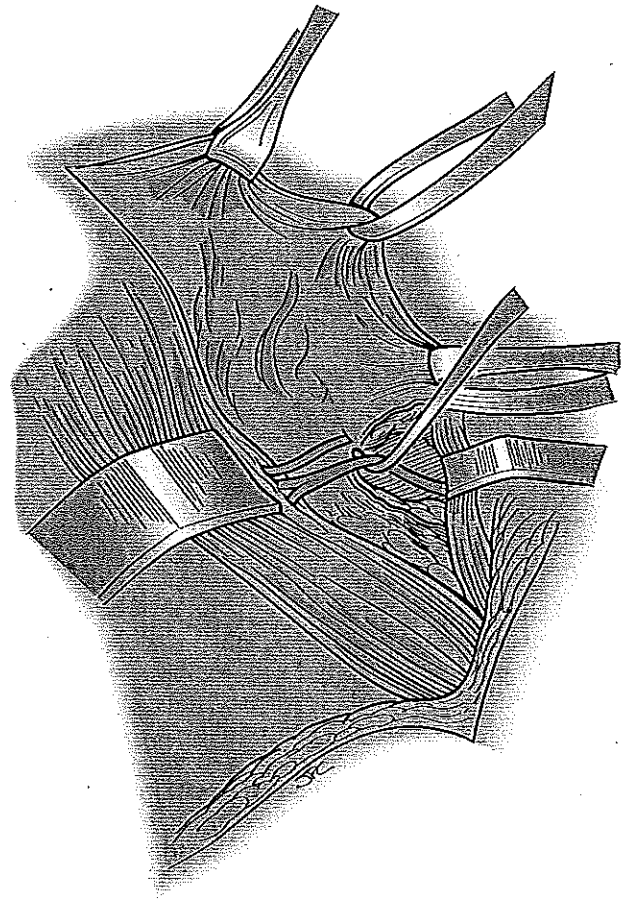
The 11th nerve is encountered where it enters the SCM at a point approximately 2 finger breadths below the posterior belly of the digastric muscle (Fig. 78-42). If the patient is not paralyzed and electrocautery is used for dissection, the nerve will be stimulated, assisting in nerve identification. The angle between the SCM and the posterior belly of the digastric muscle should be identified at this point. The branch of the 11th nerve to the SCM can usually be identified and is preserved, although adjacent vessels must be divided. The 11th nerve is then dissected free from the node-bearing adipose tissue in level II by dissecting along the superior surface of the nerve to the point at which it dives under the posterior belly of the digastric muscle, usually immediately lateral to the IJV. This requires dividing the surgical specimen lateral to the nerve. As the tissue lateral to the nerve is divided, care must be taken not to inadvertently divide enlarged lymph nodes (Fig. 78-43).



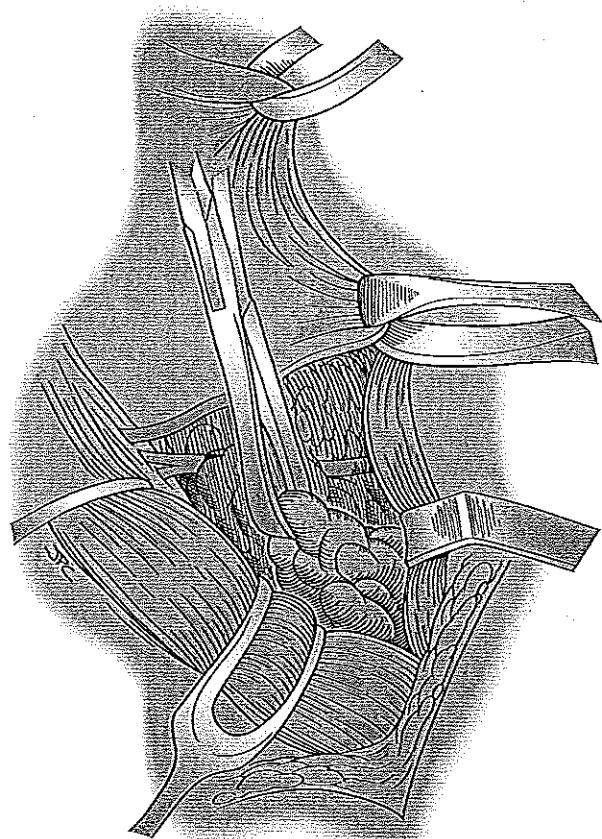
**Figure 78-42.** Identification of the 11th nerve entering the sternocleidomastoid muscle. Generally, several vessels are near this point. Identification is easier if no paralytic agents are used.

Typically the occipital artery lies just under the inferior border of the posterior belly of the digastric and just lateral to the nerve. The 11th nerve has been reported to pass deep to the IJV in some cases. In these cases, the vein could theoretically be inadvertently divided, and care should be taken to avoid this error in technique.

Once the digastric muscle and the posterior corner have been identified, sharp dissection or electrodissection is used to free the tissue in this corner. The fibrofatty tissue is grasped with an Allis clamp (Fig. 78-44) and is retracted inferiorly and dissected free from the digastric muscle and SCM down to the underlying deep cervical musculature (Fig. 78-45). Branches of the occipital artery encountered under the inferior edge of the digastric muscle may need to be ligated. The dissected tissue is freed from the SCM down as far as the 11th nerve and elevated anteriorly in a plane just lateral to the deep cervical muscles. It is then passed anteriorly under the 11th nerve (Fig. 78-46). Freeing the tissue requires division of the fat pad deep to the posterosuperior portion of the SCM. Some surgeons do not remove the posterior segment of level II, but rather extend the resection only as far posteriorly as the 11th nerve.



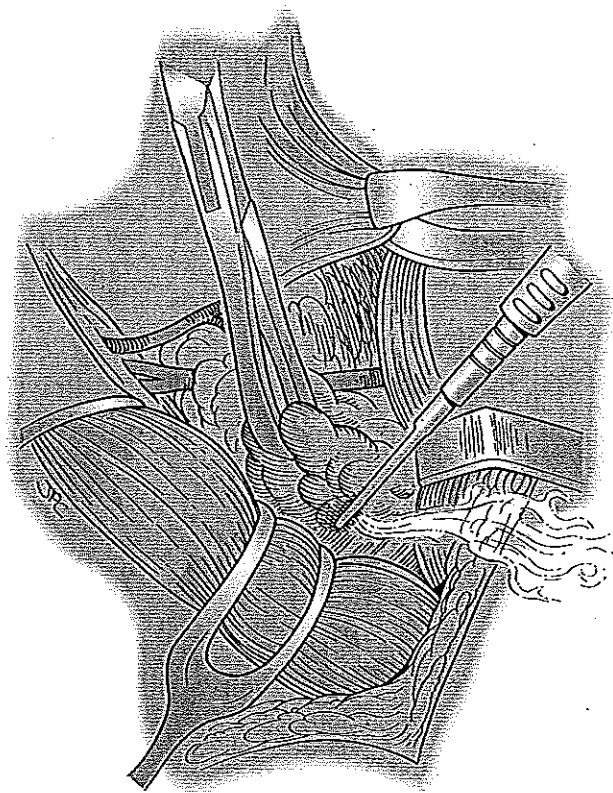
**Figure 78-43.** Dissection of the 11th nerve up to the posterior belly of the digastric muscle.



**Figure 78-44.** The fibroadipose tissue is grasped just inferior to the angle formed by the posterior belly of the digastric muscle and the sternocleidomastoid muscle.

The fascia deep to the undersurface of the SCM is divided, and the cervical nerves are identified in the fatty tissue immediately anterior to the posterior border of the SCM (Fig. 78-47). Care must be taken at this point to avoid injury to the 11th nerve, which may exit the SCM in this region. The cervical plexus is preserved by keeping the dissection lateral to the cervical nerves. It is not necessary to incise these nerves because they provide a clear landmark and the posterior deep margin to the dissection in this region. Dissection is then carried anteriorly in a plane lateral to the cervical nerves to the carotid sheath and IJV, which is identified from the level of the omohyoid muscle up to the digastric muscle. As the fascia is incised over the IJV, the nodes and fatty tissue are rolled anteriorly and the IJV is exposed and freed from the overlying fascia (Fig. 78-48). The ansa cervicalis must be divided at this time and occasionally causes anxiety if it is mistaken for the phrenic nerve. Use of a nerve stimulator is an expeditious means to ensure the nerve identified as ansa is indeed ansa. Care must be taken to avoid inadvertently dividing the 11th nerve in the course of the procedure.

Multiple small tributary veins will need to be ligated as the IJV is unwrapped. The common facial vein trifurcation is often large and should be divided at some distance from the IJV to avoid narrowing the IJV because

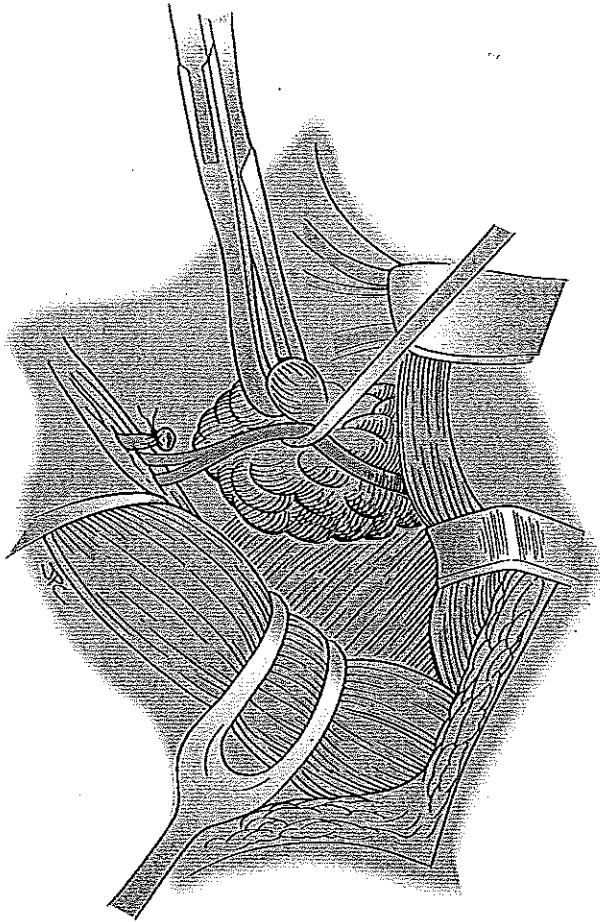


**Figure 78-45.** Incising the posterosuperior pedicle of tissue free from the digastric and sternocleidomastoid muscles down to the deep cervical muscles. The pedicle is elevated from the deep muscles in a posterior-to-anterior direction.

of ligation at this point (Fig. 78-49). If the vein is torn, it can frequently be salvaged with 6-0 vascular sutures. Unfortunately, this is time consuming, and injury is better avoided than repaired. Placing the fascia and vein on stretch and using a knife is generally the easiest way to avoid bleeding. If level IV dissection is to be performed, the IJV is identified inferior to the omohyoid muscle and anterior to the lymphatic pedicle (see Fig. 78-27). The pedicle is isolated; care is taken to avoid injury to the brachial plexus, phrenic nerve, the carotid artery, and the vagus nerve; and the pedicle is clamped and divided. This is particularly important on the left side.

The node-containing tissue is then dissected from the carotid sheath in an inferior-to-superior direction. The ansa hypoglossal nerve often can be preserved and will serve as a landmark to help identify the hypoglossal nerve. The ranine veins that form a plexus around the hypoglossal nerve are clamped and divided (see Fig. 78-32). Care must be taken to avoid injury to the superior laryngeal nerve; this can best be accomplished by identifying and preserving the superior thyroid artery. Dissection is carried anteriorly along the hypoglossal nerve, and the digastric muscle and the specimen can be easily removed at this point.

Nodal areas are best identified by the pathologist when the specimen is marked before removal because



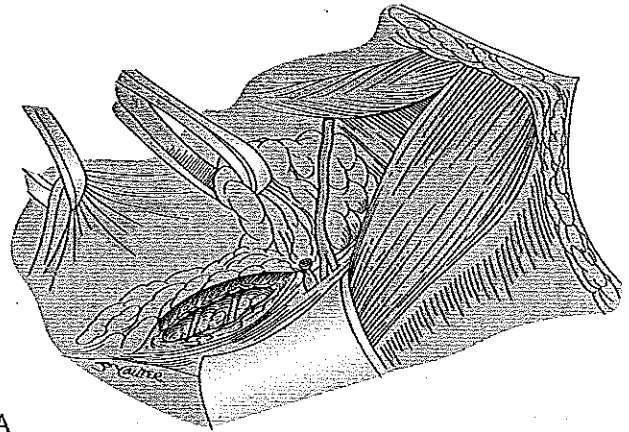
**Figure 78-46.** The dissected tissue is passed anteriorly under the elevated nerve.

the absence of identifiable structures will make orientation of the specimen for pathologic study difficult. Hemostasis is ensured, and the wound is irrigated, drained, and closed in layers.

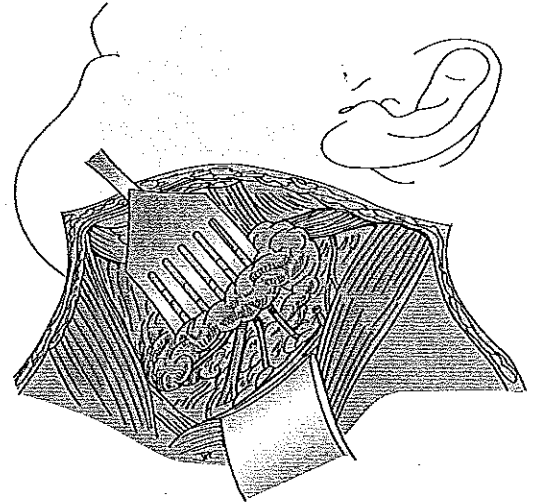
## POSTEROLATERAL NECK DISSECTION

Various extended neck dissections can be performed in conjunction with either comprehensive or selective neck dissections. Extended neck dissections include dissections that remove retropharyngeal nodes, paratracheal nodes, and the suboccipital and retroauricular nodes. Inclusion of the latter groups of nodes, "posterolateral neck dissection"<sup>24</sup> is the most common form of extended neck dissection.

Two distinct groups of nodes can be identified in the upper posterior neck. One group is just lateral or posterior to the mastoid, and the other, the suboccipital group, lies near the insertion of the trapezius muscle into the inferior nuchal line. These nodes can be involved as first echelon nodes in cutaneous lesions of the scalp and therefore should be removed during neck dissections performed for malignancies of the skin of the posterior scalp.



A



B

**Figure 78-47.** A, Incision of the fascia deep to the sternocleidomastoid muscle to expose the cervical nerves. Note that the posteroinferior limit of dissection is rather arbitrary. B, Dissection is kept anterior to the cervical nerves, thereby protecting the cervical plexus.

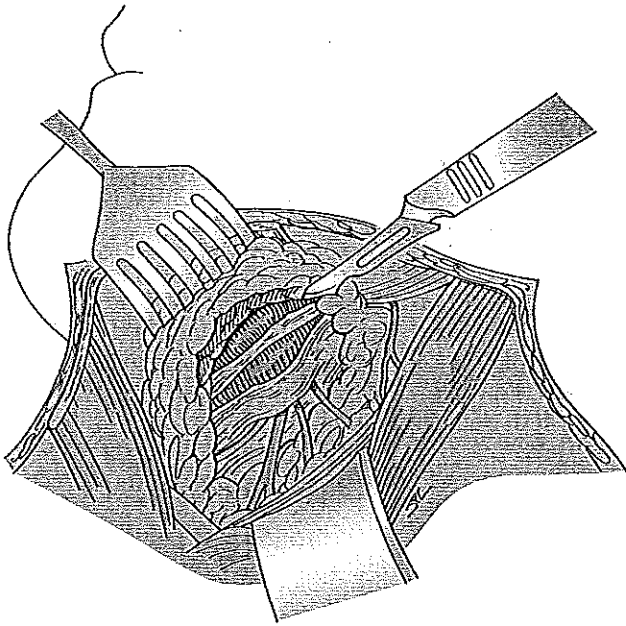
## PATIENT SELECTION FOR POSTEROLATERAL NECK DISSECTION

Lesions involving the skin of the scalp, such as malignant melanoma or squamous cell carcinoma, can drain either to the suboccipital and postauricular nodes or to the preauricular and parotid nodes, depending in part on the position of the primary lesion. As a result, neck dissections performed for malignancies of the scalp should include one or both of these regions in conjunction with the neck dissection. A more in-depth discussion of the decisions involved in this section can be found elsewhere.

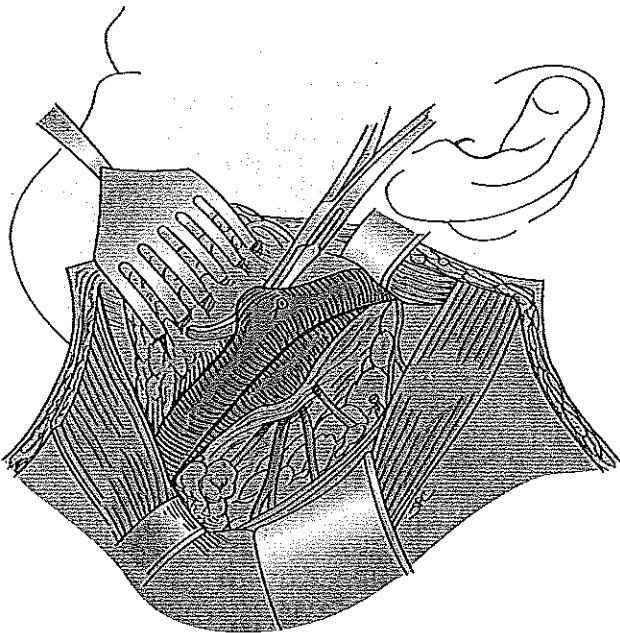
## TECHNIQUE

The skin incision should be extended somewhat further posteriorly than for a routine neck dissection to gain access to the posterior-superior neck and nuchal region. Positioning of the patient is somewhat more critical in that access to the posterior neck will be required. Skin flaps are elevated posteriorly superficial to the trapezius





**Figure 78-48.** Exposure of the internal jugular vein (IJV) and rolling the fascia, containing lymphatics and nodes, off the IJV. Use of a sharp knife with firm countertraction is key here. Avoid tearing small tributaries.



**Figure 78-49.** Division of the common facial vein, preserving a stump on the internal jugular vein to avoid narrowing the vein unnecessarily.

to the nuchal line and the spinous processes. The trapezius muscle is then separated from the nuchal line and from the spinous processes down to the third or fourth cervical vertebra. Usually branches of the occipital artery will be encountered and must be ligated. The dissection of the posterior triangle is thereby extended deep to the trapezius muscle, and fat and nodes super-

ficial to the upper portions of the splenius capitis and levator scapulae are resected. As in other forms of neck dissection, the spinal accessory nerve is preserved if this is feasible, although nodal involvement may require sacrifice.

The remainder of the procedure is performed in a manner similar to that for a routine comprehensive neck dissection. In most cases, dissection of level I will be unnecessary. However, the upper and midjugular nodes, as well as those in level V, should be removed.

## POSTOPERATIVE MANAGEMENT

Drains are used in the management of all types of neck dissection. We use two drains per side for a total of four drains for bilateral neck dissections. Either  $\frac{1}{8}$ -inch Hemovac or Jackson-Pratt drains are used. We have found that maintenance of drain patency is more dependent on skilled nursing care than the size or brand of the drain. Drains are aspirated by the nurses at least once per shift. The drain connector is prepped with povidone-iodine (Betadine) solution, separated under aseptic conditions, and aspirated with a 10-mL syringe. Drains are maintained on suction from the time they are placed in the neck until they are removed. Drains that are left off suction for an appreciable period (e.g., during closure of the neck incision) often become filled with clot and will not function.

A compression dressing is used by some of our surgeons unless bilateral neck dissection or flap reconstruction has been performed. Functioning drains and a pressure dressing together serve to increase the efficacy of flap coaptation and reduce the incidence of postoperative seromas, hematomas, and flap edema. The dressing is left in place and not removed or changed unless soaked or soiled. Cosmetic reinforcement of the dressing is often necessary, and the dressing is removed in 5 days or when the drains are removed. Drains are maintained until they are draining less than 10 mL per 24 hours. Establishing a minimal threshold of drainage will ensure that drains are not removed too soon. It is better to leave drains in several days longer than it is to remove them even 1 day too soon. Antibiotics are administered perioperatively and for 24 hours following surgery. We do not routinely use antibiotics throughout the time that the necks are drained because there is no evidence that wound infections develop secondary to retrograde contamination through drain sites.

Physical therapy of the shoulder must be initiated early in all patients in whom the 11th nerve was dissected. This is particularly critical in those in whom it has been sacrificed. This should include primarily range-of-motion exercises to prevent shoulder fibrosis. Therapy should begin before patient discharge, and the patient should be instructed in at-home exercises.

## COMPLICATIONS OF NECK DISSECTION

Complications of neck dissection can be attributed to preoperative, intraoperative, and postoperative factors. Many of these factors are errors. Head and neck surgi-

cal services should implement standardized protocols to reduce the chances of errors occurring, or reduce the effect on the patient if they occur. Some preoperative errors that can lead to complications follow:

1. Selection of inappropriate management strategy for the patient. Often, this takes the form of not performing a neck dissection when the site or stage of the primary lesion suggests that treatment of the neck is required.
2. The decision to perform a unilateral neck dissection when bilateral dissections are indicated will lead to an unacceptable rate of contralateral recurrences.
3. Failure to use perioperative antibiotics when the aerodigestive tract is opened through the neck.
4. Failure to plan incisions correctly, particularly when performing bilateral neck dissections.

### *Intraoperative Misadventures*

Intraoperative misadventures in the neck can be catastrophic. Injury to the brachial plexus, phrenic nerve, or carotid artery can lead to significant disability or death in the postoperative period. The phrenic nerve and brachial plexus are protected by identification early in the performance of a radical neck dissection. Injury is avoided in the selective neck dissection by maintaining the dissection plane anterior to the cervical nerves (see Figs. 78-47 and 78-48). If at any time the position of the phrenic nerve and brachial plexus is questioned, the operator should immediately identify the omohyoid muscle, dissect the fascia deep to the muscle, and identify the brachial plexus and the phrenic nerve before proceeding further. Although many patients can survive with one phrenic nerve injured, phrenic nerve injury is not compatible with a smooth postoperative course. Most head and neck patients, particularly those undergoing procedures on the upper aerodigestive tract, have chronic obstructive lung disease and will not tolerate even a unilateral phrenic nerve injury. Injury to the carotid artery can be avoided by careful dissection in the carotid sheath after the cervical nerves are divided in a radical neck dissection. Careful dissection anteriorly following division of cervical nerves will frequently reveal that the internal carotid artery is more posterior than expected, particularly in the elderly patient with an ectatic artery.

A chyle fistula can be catastrophic and usually occurs when the ducts are interrupted by injudicious dissection posterior to the inferior aspect of the IJV. Injury can be avoided by ligating the entire lymphatic pedicle en bloc, particularly on the left side, rather than dissecting through the pedicle and searching for the elusive thoracic duct (see Figs. 78-29 and 78-30). If chyle is encountered during the procedure, an exhaustive search should be made for the leak. It must be recalled that chyle is not milky in the fasting patient. The use of an operating microscope is frequently helpful in this situation. The intraoperative use of fibrin glue may reduce the likelihood of postoperative fistula.<sup>12</sup>

Injury to the midportion of the jugular vein is not to be considered a problem unless the jugular veins are

sacrificed bilaterally. This is occasionally necessary because of the extent of disease, but it should not be required for technical reasons. Care must be taken in dividing the jugular vein inferiorly to avoid injury to the inferiorly located middle thyroid vein. The excessive bleeding can precipitate the loss of control of the inferior portion of the divided jugular vein. Lack of control under the clavicle can be catastrophic and require the assistance of a thoracic surgeon for salvage. Superiorly, the problem is not as severe because the vein can usually be plicated with the posterior belly of the digastric muscle and bleeding controlled. We believe that reconstruction of one vein is feasible and indicated if unanticipated sacrifice of the contralateral vein must be performed. Although most patients recover uneventfully following bilateral IJV sacrifice, the decrease in postoperative morbidity would seem to make reconstruction worthwhile.

Dissection along the carotid bulb can result in intraoperative bradycardia. Injection of lidocaine *without* epinephrine will ablate this response and enable the procedure to be continued. Injury to the external carotid system is usually not significant. Injury to the internal carotid artery, however, may result in stroke from either acute loss of blood flow or secondary embolization from the distal segment. Air embolism through open cervical veins is rare unless the procedure is being performed with the head elevated. The pathognomonic sign is "gurgling" heard via the precordial cardiac stethoscope and associated loss of blood pressure. If air embolism is encountered or suspected, the patient should immediately be turned onto his or her left side and the central venous line aspirated. If no central line is in place, one should be placed immediately. If death seems imminent, direct left ventricle puncture and aspiration should be attempted and may be lifesaving. Careful preoperative assessment and intraoperative techniques will avoid this and other complications.

Injury to the marginal mandibular nerve can be avoided by dissecting the nerve free and reflecting it superiorly. Care must be taken posteriorly because the nerve frequently dives farther inferiorly than is appreciated. Dissecting the tail of the parotid free from the digastric muscle and reflecting it superiorly will often help to prevent marginal mandibular nerve injury. If the tail of the parotid is resected, the nerve should be dissected into the gland before blindly excising parotid tissue.

The tracheostomy incision is usually incorporated into the neck wound. Several absorbable sutures should be used to sew the skin flap to the underlying structures to prevent soilage of the wound.

## MANAGEMENT OF POSTOPERATIVE COMPLICATIONS

Most postoperative complications are due to errors in patient selection, preoperative planning, or surgical technique. Avoidance of complications should be a primary goal of treatment—second only to control of

disease. Unfortunately, regardless of the skill of the surgeon and the team, complications will occur in all centers that manage cancer of the head and neck. Knowledge of the range of these complications can reduce the long-term morbidity for the patient.

### Chyle Fistula

Profuse neck drainage, especially from the left-sided neck drains, suggests the presence of a chyle fistula. Drainage output in the range of 1 to 2 L in 24 hours suggests either fistula or salivary leak. Initial management includes pressure dressings and dietary supplementation with medium-chain triglycerides. Intravenous hyperalimentation sometimes is required.

Once a chyle leak has been identified, treatment is required. Instillation of fibrin glue through the drain may provide benefit for some patients, although early exploration is the treatment of choice. The use of an operating microscope or surgical loupes is mandatory for most surgeons, because identification of the leaking vessel is often difficult. Feeding the patient a high-fat meal immediately before surgical exploration will assist in identification of the leak. Once identified, it should be controlled with small sutures (e.g., 5-0 or 6-0 nylon or similar suture). Large bites of tissue with large sutures tend to pull through the thin walls of the ducts. Application of fibrin glue to the surgical bed may reduce the probability of recurrence. A pressure dressing consisting of adhesive elastic dressing material passed over the shoulder and attached anteriorly and posteriorly may help in the management of the complication.

An occasional patient requires intrathoracic ligation of the thoracic duct. Recently a thoracoscopic technique was described that may avoid open thoracotomy.<sup>25</sup>

### Hematoma or Seroma

Hematoma occurring in the immediate postoperative period is often due to inadequate hemostasis. Although theoretically drains should permit the removal of blood, the quantity of blood that can be satisfactorily removed by functioning drains is limited. If the bleeding exceeds the drain capacity, a hematoma will result. Once this occurs, it can be assumed that a clot has formed in the wound, the drains have become nonfunctional, and reexploration is mandatory. Attempts to aspirate a hematoma in the postoperative period are doomed to failure, because it is unlikely that the clot can be satisfactorily removed through even a large-gauge needle. The wound should be reexplored as soon as possible. This usually means returning to the operating room on the same day (or evening) of the procedure, reopening the wound, irrigating it to remove the clot, identifying the bleeding vessels, and replacing the now-clotted drains. Most frequently no bleeding site is identified. However, a careful search occasionally reveals one or more bleeding sites. During reexploration, it is worthwhile to ask the anesthetist to allow the blood pressure to creep up toward the higher levels to prevent missing a vessel that is not bleeding merely because of hypoten-

sion and vasoconstriction. Fluid resuscitation and blood replacement may be necessary. The most difficult part of this procedure is usually deciding to return to the operating room and speaking with the family, because the actual reexploration is not technically difficult. Early return to the operating room for exploration is necessary for a number of reasons, the most critical of which is the risk of skin flap loss owing to pressure from an undrained hematoma.

Postoperative hematoma occurs either to excessive bleeding or failure of evacuation of the blood that oozes from the surgical bed. The most common cause is lack of adequate hemostasis, not nonfunctional drains that have been left off suction for too long (usually during wound closure) and have clotted. This complication is prevented by adequate hemostasis during neck dissection. If a clot is noted in the wound at the completion of the closure and the drains do not appear to be working, it is best to reopen the wound, irrigate it to remove the clots, identify the source of bleeding and ligate or cauterize them, and replace the drains. Nursing personnel must be aware of both the importance of continuous suction on the drains and the significance of closely monitoring drain function. We use wall suction for the first 24 to 48 hours to ensure high suction and thereafter routinely aspirate the drains with a syringe to prevent accumulation of debris that would obstruct the drains.

A seroma develops later in the postoperative course. This is most commonly due not to failure of the drains but to overenthusiastic early drain removal. Often, the goal of early discharge leads to premature drain removal. As stated earlier, leaving the drains in place for an additional day or 2 is far better than removing them even 1 day too early. We maintain that drainage must be less than 10 mL in 24 hours before drains are removed. Many patients are now discharged with drains in place and are instructed in drain management. The drains are removed on a postoperative visit. This strategy results in an extremely low incidence of postoperative seroma, although it does produce prolonged drainage in some patients, primarily those who have undergone bilateral neck dissection. If drainage persists for longer than 10 to 14 days, we assume that the neck flaps have "stuck" and will pull the drains regardless and apply a pressure dressing.

### Skin Flap Loss

Skin flap loss can be catastrophic in the performance of a radical neck dissection because it can lead to exposed vital structures, primarily the carotid artery. The carotid artery, particularly when previously irradiated, does not tolerate exposure and must be covered early. Avoidance of skin flap loss is significantly easier than management of the complication once it has developed. Prevention includes the selection of appropriate incisions to avoid long, narrow, poorly vascularized flaps. Preservation of the platysma muscle may help if it is oncologically feasible to do so. Avoidance of inappropriate devascularization of the skin flap or retaining

specific vessels, such as the facial artery (if oncologically feasible) may help. Prolonged skin flap retraction, such as suturing the flap to the drapes during a lengthy procedure, can cause kinking of the venous structures in the flap, resulting in stasis and decreased viability. It is wise to periodically return the flap to its anatomic position when attention in the operative field is directed elsewhere. It is also wise to keep the flap moist with saline-soaked sponges to avoid desiccation of the feeding vessels.

If skin flap loss occurs, an initially conservative approach is warranted. Often the underlying dermis remains viable, whereas the epidermis becomes necrotic and is lost. However, if the carotid artery is exposed because of full-thickness loss, some form of coverage is mandatory. This will include flap coverage, either pedicle skin flap such as deltopectoral flap or muscle flap such as pectoralis or trapezius. These are major procedures but warranted when exposed carotid artery is at risk following skin flap loss.

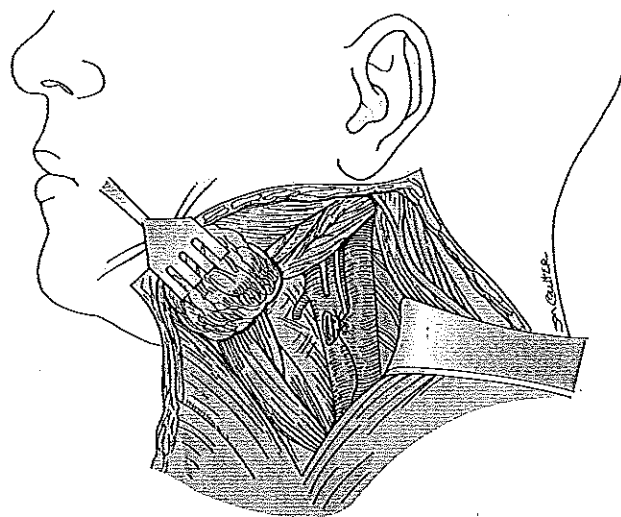
### Bilateral Internal Jugular Vein Sacrifice

We believe that maintenance of one IJV is critical to prevent the development of the postoperative sequela of IJV sacrifice. We take pains to preserve one vein if feasible. If vein preservation is not feasible, we have occasionally used intraoperative IJV reconstruction and have found that an uninvolved segment of contralateral IJV is often of ideal size and easily accessible. If bilateral IJV or second IJV sacrifice is required, postoperative head and neck swelling will probably be significant. Airway management with a tracheostomy is mandatory because upper airway obstruction is common. The head of the bed should be elevated, and care must be taken to monitor the patient for the syndrome of inappropriate antidiuretic hormone. Although stroke, blindness, and even death have been reported, most of these patients suffered major blood loss and hypotension in addition to the IJV compromise. It also seems possible that some of the earlier reports of poor patient outcome following bilateral IJV sacrifice were secondary to the syndrome of inappropriate antidiuretic hormone and inappropriate fluid retention that resulted in patient death. It is important to avoid a constricting dressing following bilateral neck dissections, even with vein preservation in order to avoid occluding the remaining IJV. Care should be taken during dissection to place the tie on large branches a distance from the jugular to avoid inappropriately narrowing the jugular vein (Fig. 78-50).

### Painful Shoulder Syndrome

Shoulder pain is a common sequela of neck dissection, particularly in those procedures in which the 11th nerve is sacrificed. Loss of trapezius support allows the shoulder to drop (see Fig. 78-7), resulting in decreased shoulder mobility and pain. This lends secondarily to fibrosis and further disability.

Early physical therapy is key to the prevention of this complication. Patients should be instructed to con-



**Figure 78-50.** The specimen is rolled superiorly, and the anterior dissection is completed in a manner identical to that for radical neck dissection.

tinue this therapy after discharge. It is worthwhile to ask patients about this in follow-up visits.

### SUMMARY

Cancer metastatic to the neck is the most important variable affecting survival in squamous cell carcinoma of the head and neck. Management of the neck plays a vital role in this disease. The various forms of neck dissection are important components of the head and neck surgeon's armamentarium. Dissection of clinically involved nodes, or those likely to be involved, is critical in the management of cancer of the head and neck. Selection of the appropriate form of dissection will not only improve disease control but also facilitate patient rehabilitation by reducing postoperative functional and cosmetic deficiencies (Fig. 78-51).

### PEARLS

- Imaging is often helpful in decision making in cervical lymph node metastasis.
- The potential benefit of elective neck dissection should be considered in all patients with squamous cell carcinoma of the head and neck from sites known to metastasize to the neck.
- Single modality therapy for early cancers is preferred when possible.
- Surgical management of the neck is preferable if operative therapy is selected for treatment of the primary cancer.

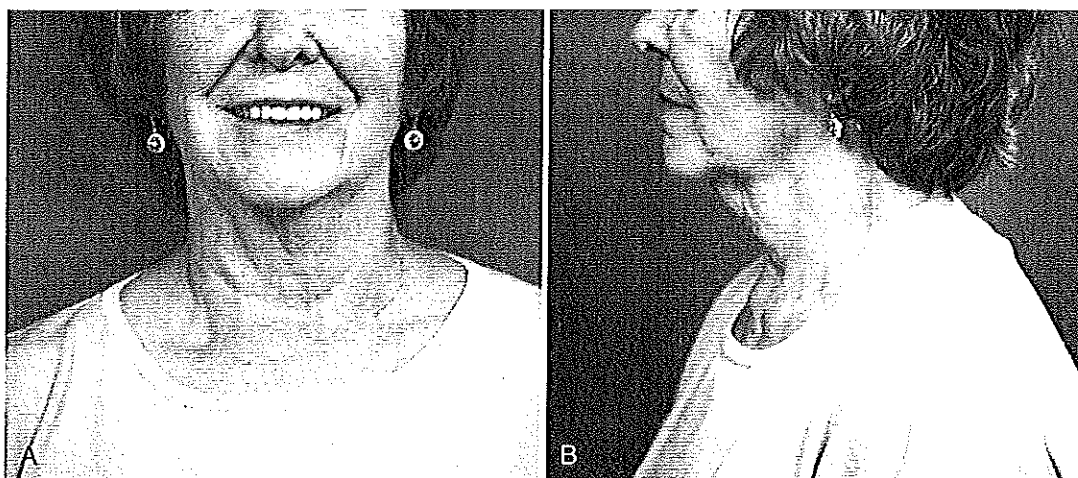


Figure 78-51. Patient 6 months after selective neck dissection.

### PITFALLS

- Inappropriate patient selection is the most common pitfall of head and neck surgery.
- Patients presenting with significant weight loss will not heal properly. They require preoperative nutritional support before surgery.
- Lack of appropriate management of fluids and electrolytes in patients with a major chyle leak jeopardizes the patient's chances for recovery.
- Failure to replace a necrotic cervical flap with a pectoralis major myocutaneous flap leaves the patient vulnerable to carotid blowout.
- Hematoma following neck dissection is caused by inadequate hemostasis not by clogged suction drains.

### References

1. Lutz C, Johnson JT, Wagner R, Myers EN: Supraglottic carcinoma: Patterns of recurrence. *Ann Otol Rhinol Laryngol* 99:12-17, 1990.
2. Layland MK, Sessions DG, Lenox J: The influence of lymph node metastasis in the treatment of squamous cell carcinoma of the oral cavity, oropharynx, larynx, and hypopharynx: N0 versus N+. *Laryngoscope* 115:629-639, 2005.
3. Johnson JT, Barnes EL, Myers EN, et al: The extracapsular spread of tumors in cervical lymph node metastases. *Arch Otolaryngol* 107:725-729, 1981.
4. van den Brekel MW, Castelijns JA: What the clinician wants to know: Surgical perspective and ultrasound for lymph node imaging of the neck. *Cancer Imaging* 23:5 Spec No A:S41-S49, 2005.
5. Crile G: Excision of cancer of the head and neck with special reference to the plan of dissection based on one hundred and thirty-two operations. *JAMA* 22:1780-1786, 1906.
6. Beahrs OH, Gossel JD, Hollingshead WH: Techniques and surgical anatomy of radical neck dissection. *Am J Surg* 90:490-516, 1955.
7. Ferlito A, Rinaldo A, Osvaldo Suárez: Often-forgotten father of functional neck dissection (in the non-Spanish-speaking literature). *Laryngoscope* 11:1177-1178, 2004.
8. Bocca E, Pignataro O: A conservation technique in radical neck dissection. *Ann Otol Surg* 81:975-987, 1967.
9. Medina JE: A rational classification of neck dissections. *Otolaryngol Head Neck Surg* 100:169-176, 1989.
10. Cappiello J, Piazza C, Giudice M, et al: Shoulder disability after different selective neck dissections (levels II-IV versus levels II-V): A comparative study. *Laryngoscope* 115:259-263, 2005.
11. Novak CB, MacKinnon SE: Patient outcome after surgical management of an accessory nerve injury. *Otolaryngol Head Neck Surg* 127:221-224, 2002.
12. Akaogi E, Mitsui K, Soharu Y, et al: Treatment of postoperative chylothorax with intrapleural fibrin glue. *Ann Thorac Surg* 48:116-118, 1989.
13. Byers RM, Wolf PF, Ballantyne AJ: Rationale for elective modified neck dissection. *Head Neck Surg* 10:160-167, 1988.
14. Fincher TR, O'Brien JC, McCarty TM, et al: Patterns of drainage and recurrence following sentinel lymph node biopsy for cutaneous melanoma of the head and neck. *Arch Otolaryngol Head Neck Surg* 130:844-848, 2004.
15. Pitman KT, Johnson JT, Eddington H, et al: Lymphatic mapping with isosulfan blue dye in squamous cell carcinoma of the head and neck. *Arch Otolaryngol Head Neck Surg* 124:455-459, 1998.
16. Kontio R, Levio I, Leppanen E, Atula T: Sentinel lymph node biopsy in oral cavity squamous cell carcinoma without clinically evident metastasis. *Head Neck* 26:16-21, 2004.
17. Som P, Curtin HD, Mancuso AA: Imaging-based nodal classification for evaluation of neck metastatic adenopathy. *Am J Roentgenol* 174:837-845, 2000.
18. Moore MG, Bhattacharyya N: Effectiveness of chemotherapy and radiotherapy in sterilizing cervical nodal disease in squamous cell carcinoma of the head and neck. *Laryngoscope* 115:570-573, 2005.
19. Kutler D, Patel S, Shah J: The role of neck dissection following definitive chemoradiation. *Oncology* 18:993-1003, 2004.
20. McHam S, Adelstein D, Rybicki L, et al: Who merits a neck dissection after definitive chemoradiotherapy for N2-N3 squamous cell head and neck cancer? *Head Neck* 25:791-798, 2003.
21. McGuirt WF, Johnson JT, Myers EN, et al: Floor of mouth carcinoma. The management of the clinically negative neck. *Arch Otolaryngol Head Neck Surg* 121:278-282, 1995.
22. Johnson JT, Bacon CW, Myers EN, Wagner RL: Medial versus lateral wall pyriform sinus carcinoma: Implications for management of regional lymphatics. *Head Neck* 16:401-405, 1994.